



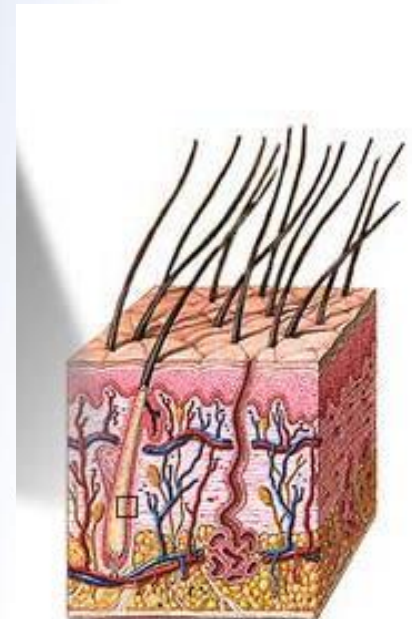
Sinclair
DERMATOLOGY

Fungal Disease of the Skin, Hair and Nails

Professor Rodney Sinclair

Sinclair Dermatology Clinic

Epworth Centre For Dermatology Research and Clinical Trials



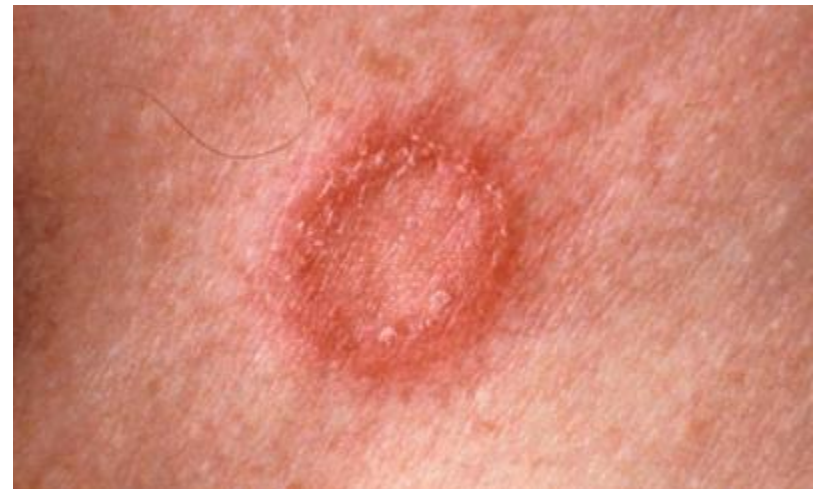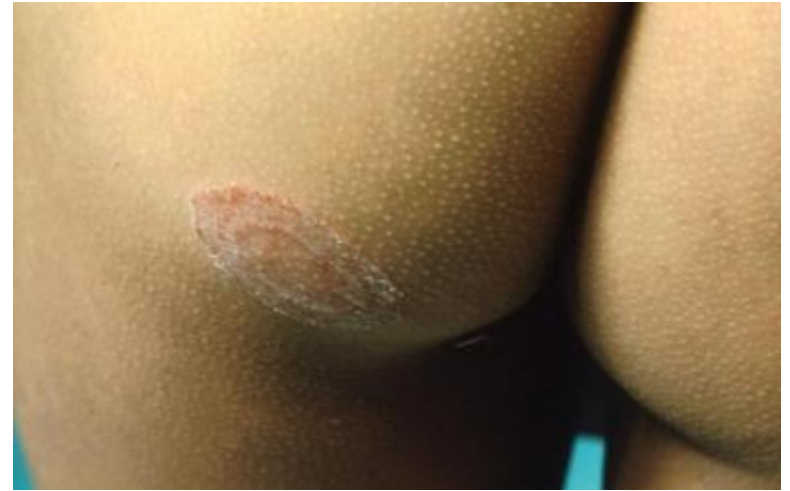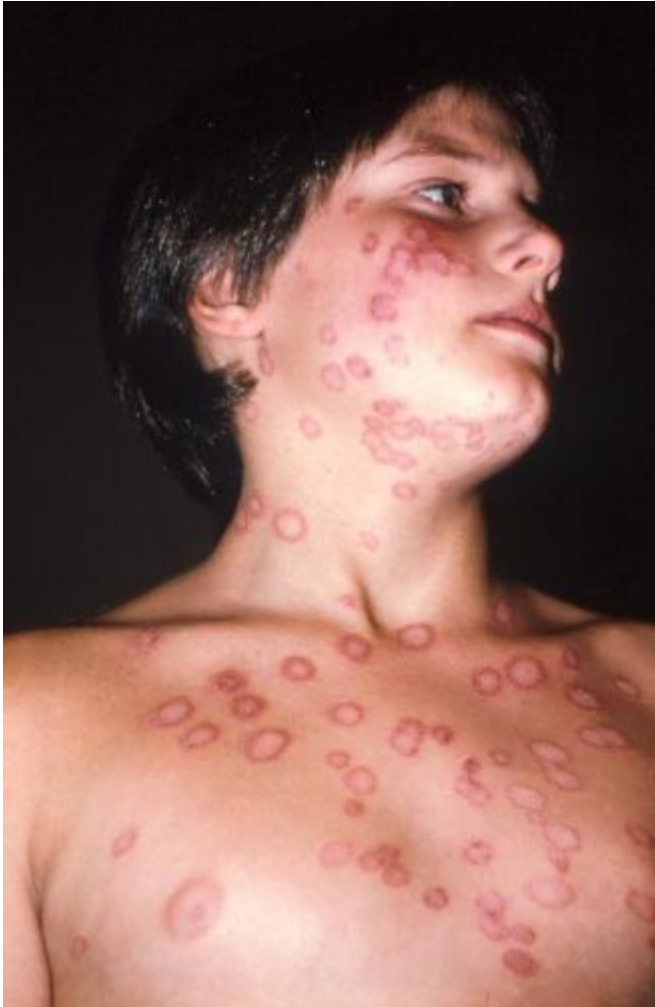Fungal Skin Conditions often present as a Red Scaly Rashes

- Fungus
- Eczema (syn. dermatitis)
- Psoriasis
- Pityriasis
- Lichen Planus
- Lupus
- Scabies

Red Scaly Rashes -Fungus

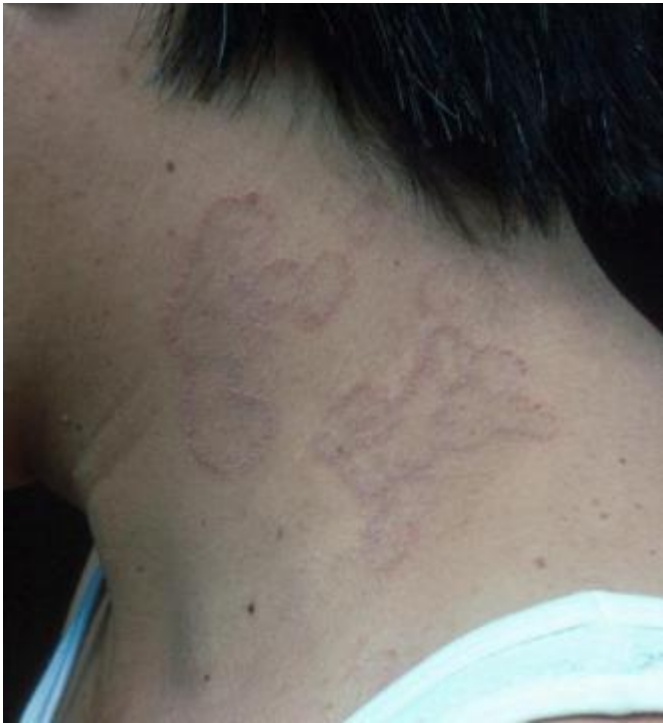- Tinea
- Candida
- Pityriasis Versicolor

Fungus

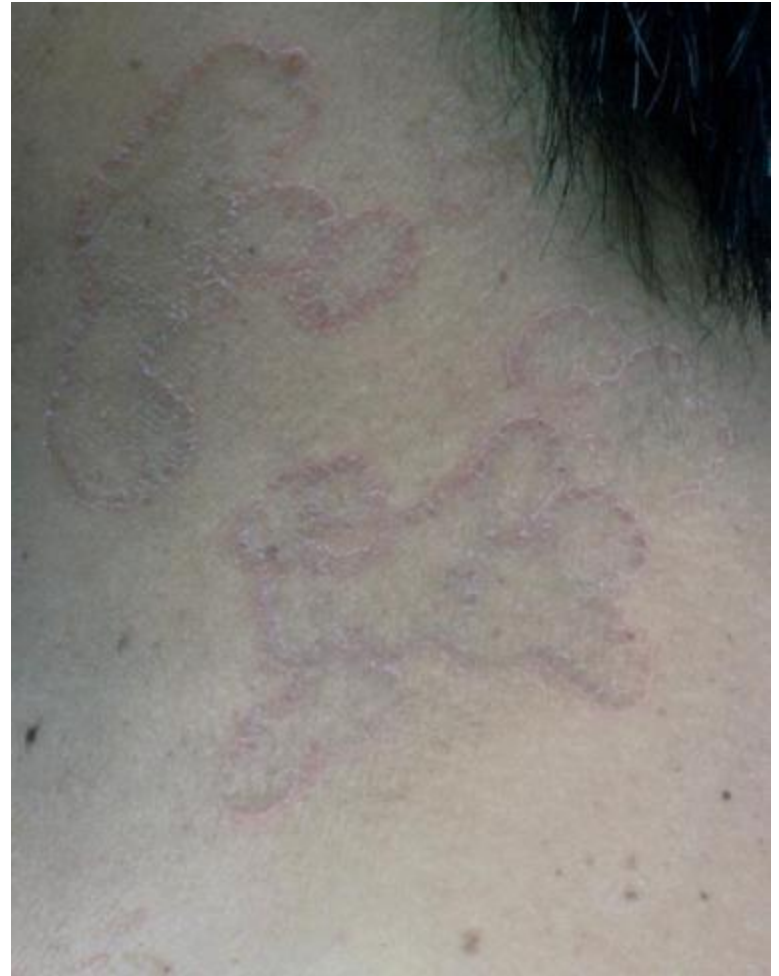

Tinea corporis (ringworm)

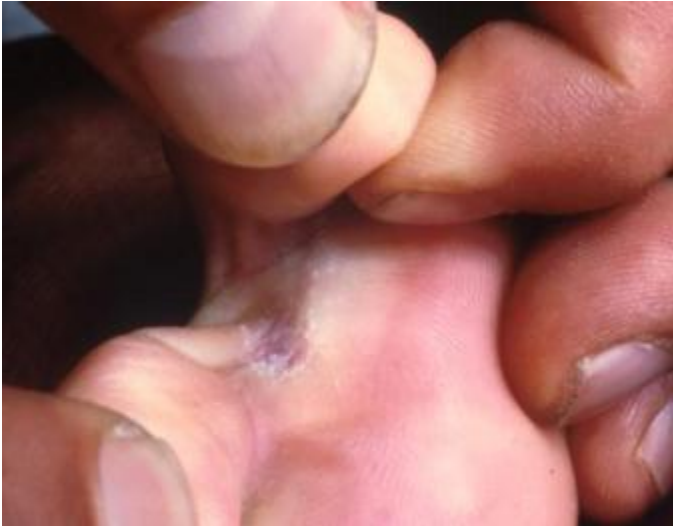Fungus



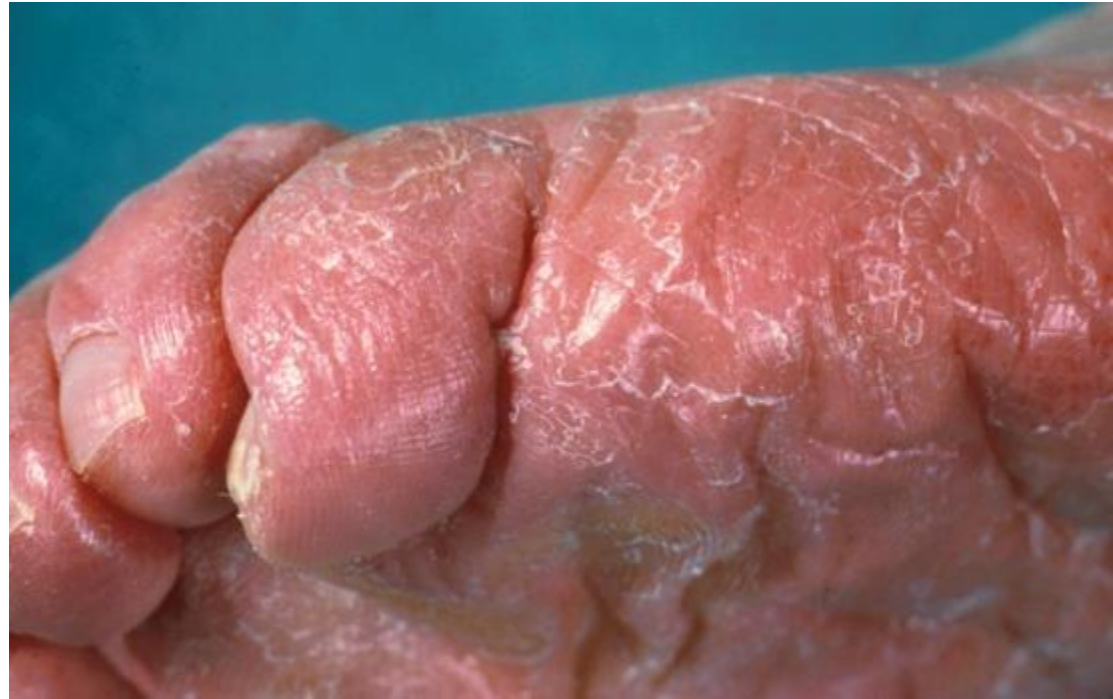Tinea corporis
(*T. rubrum*)



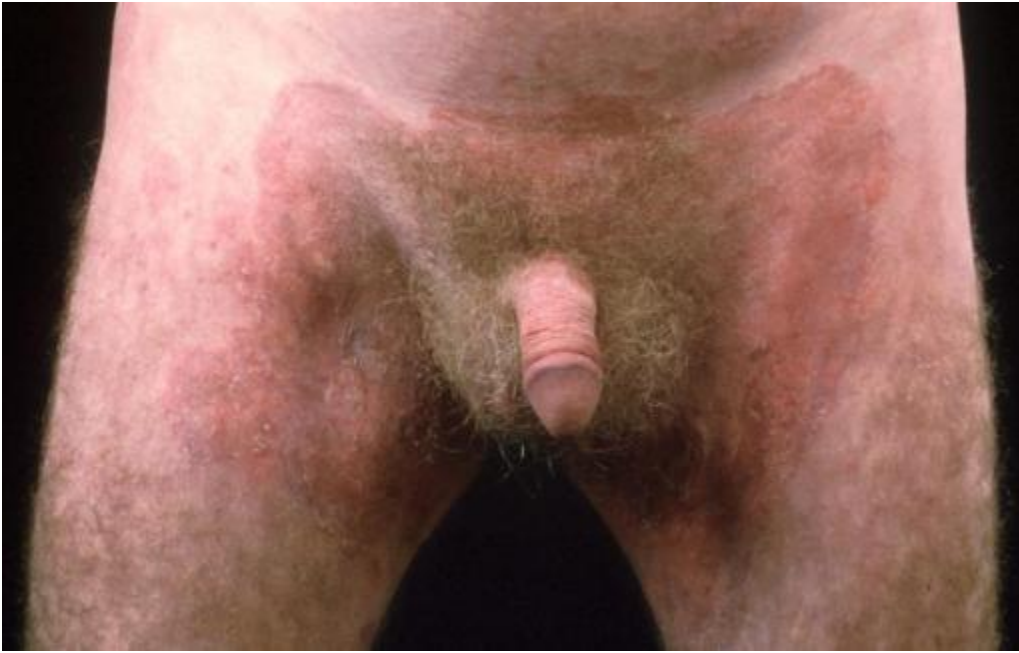Fungus



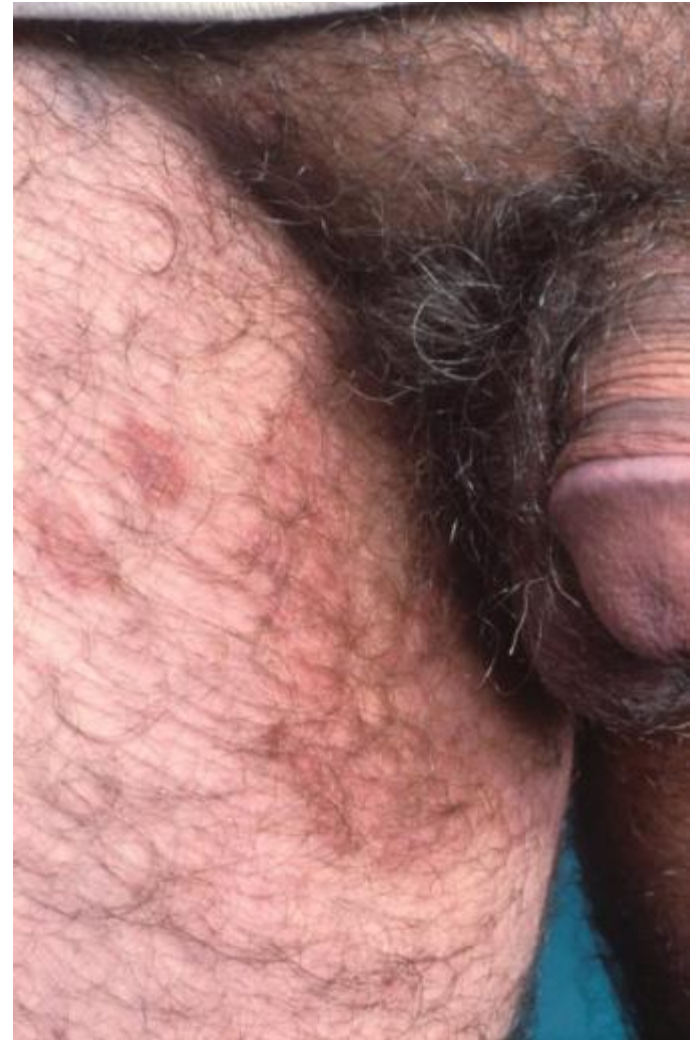Tinea pedis



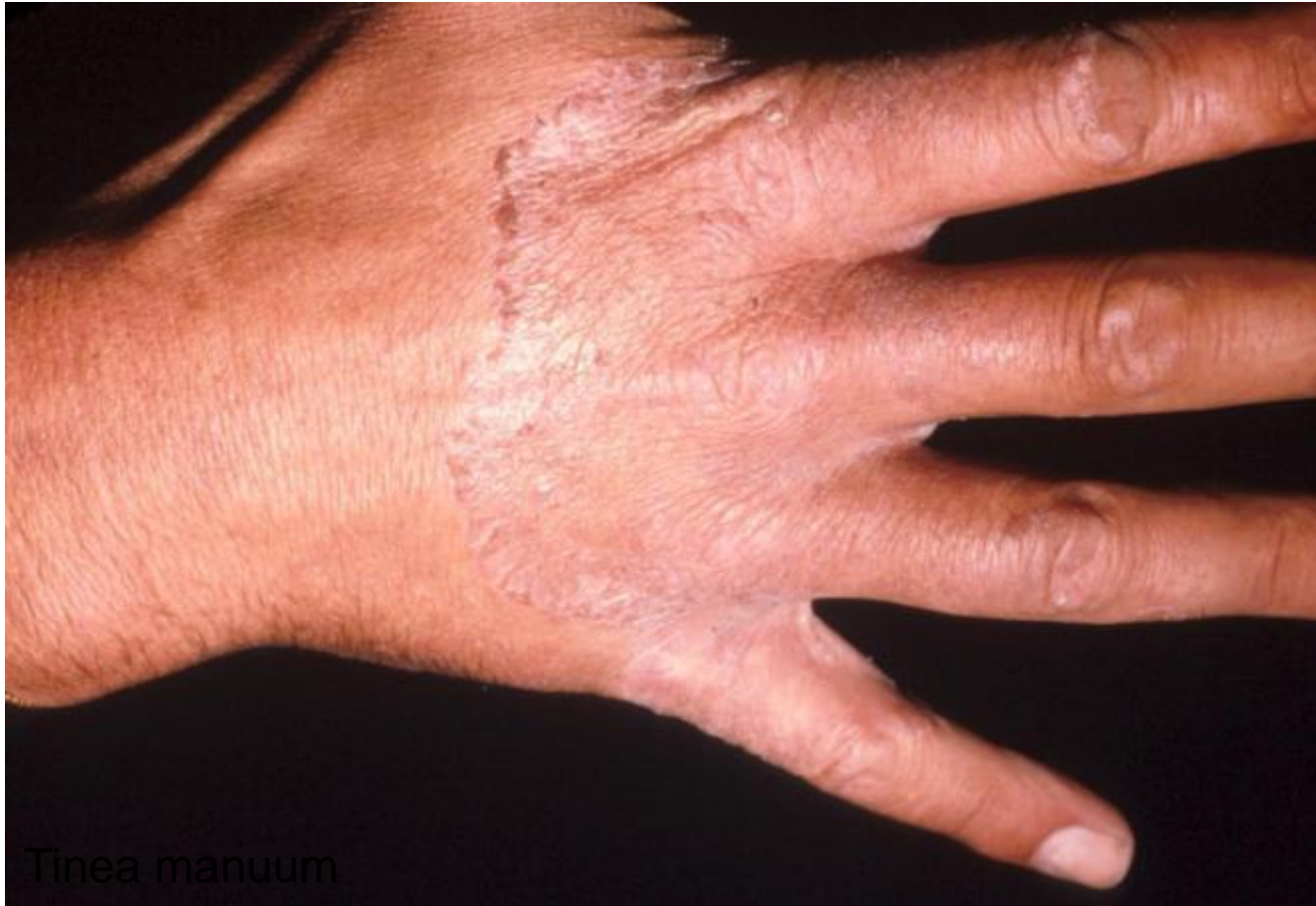Fungus



Tinea cruris

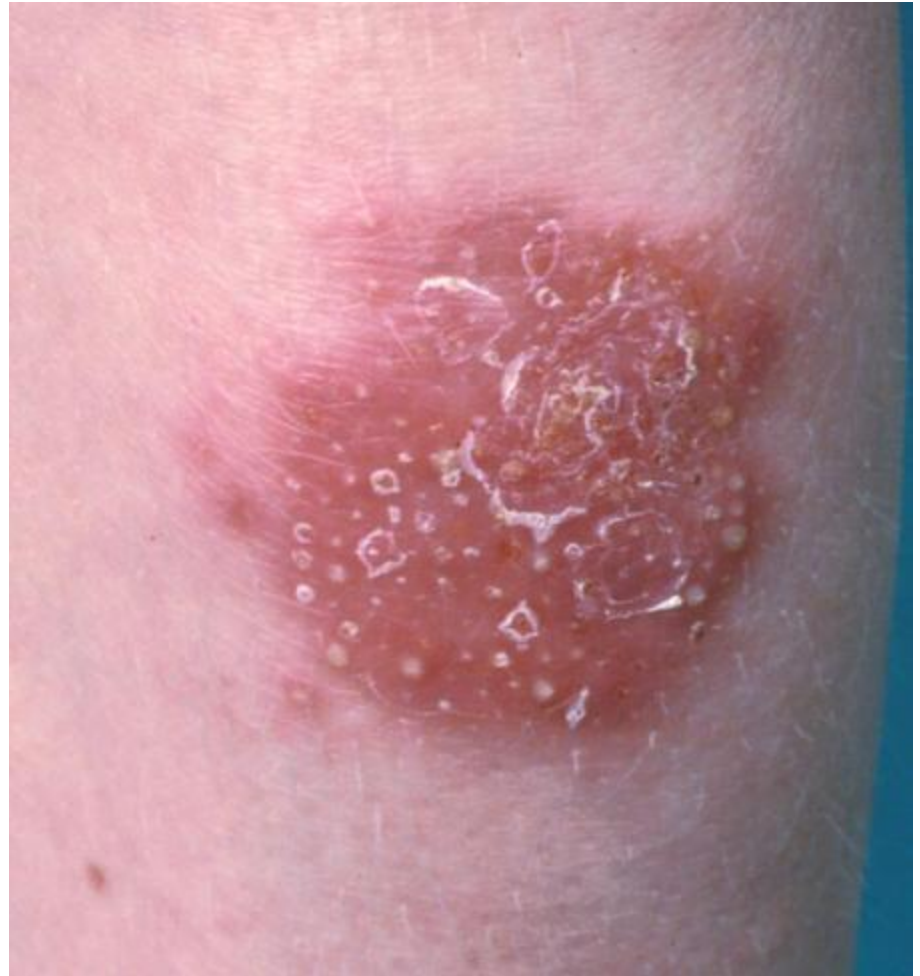

Fungus

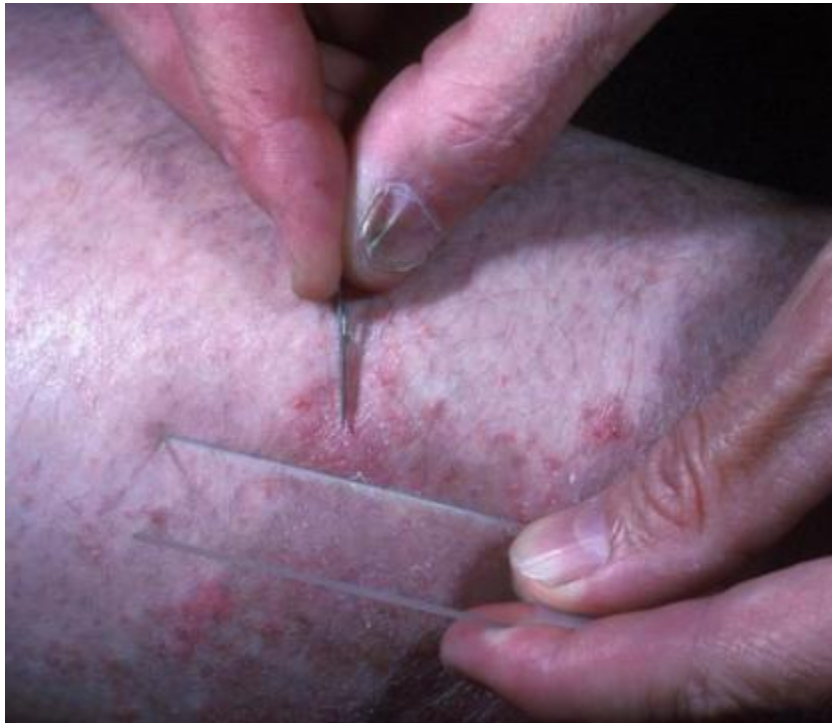

Fungus

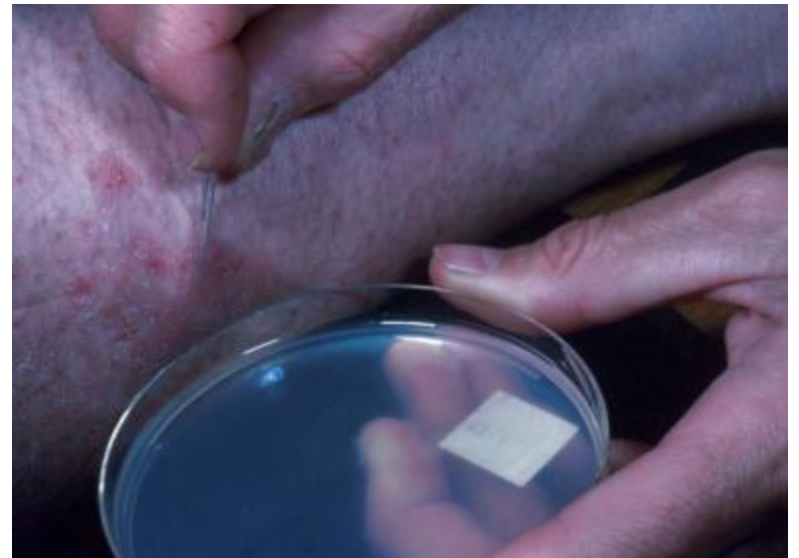Tinea incognita



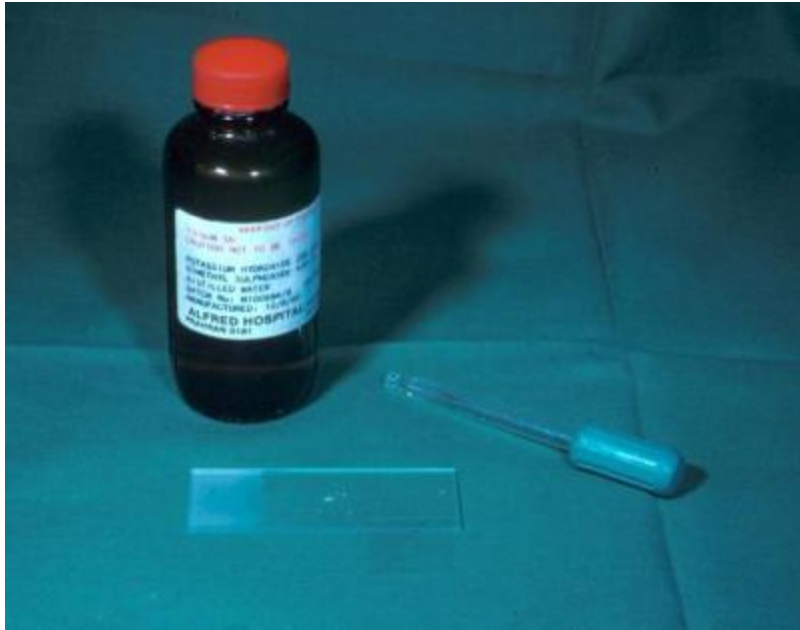Fungus



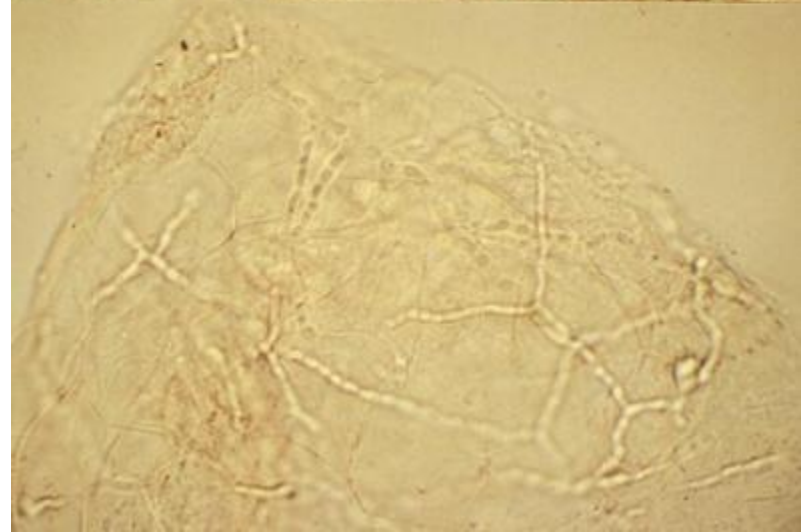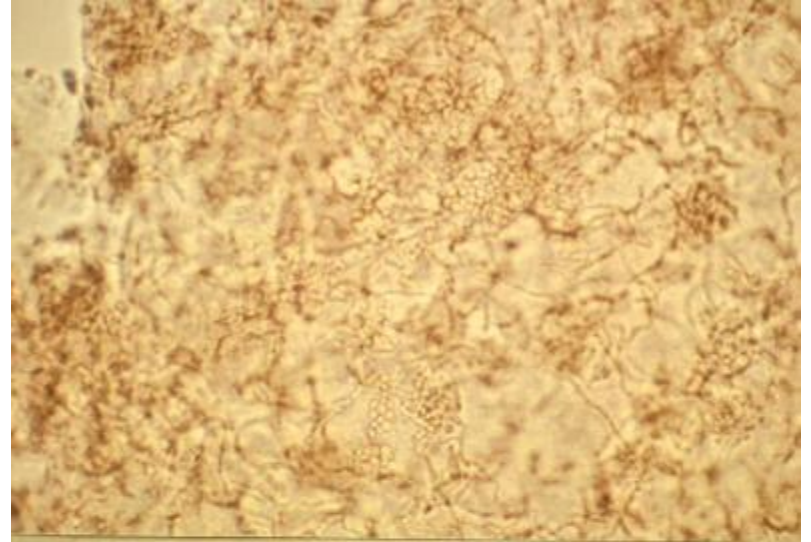
Skin scrapping



Fungus



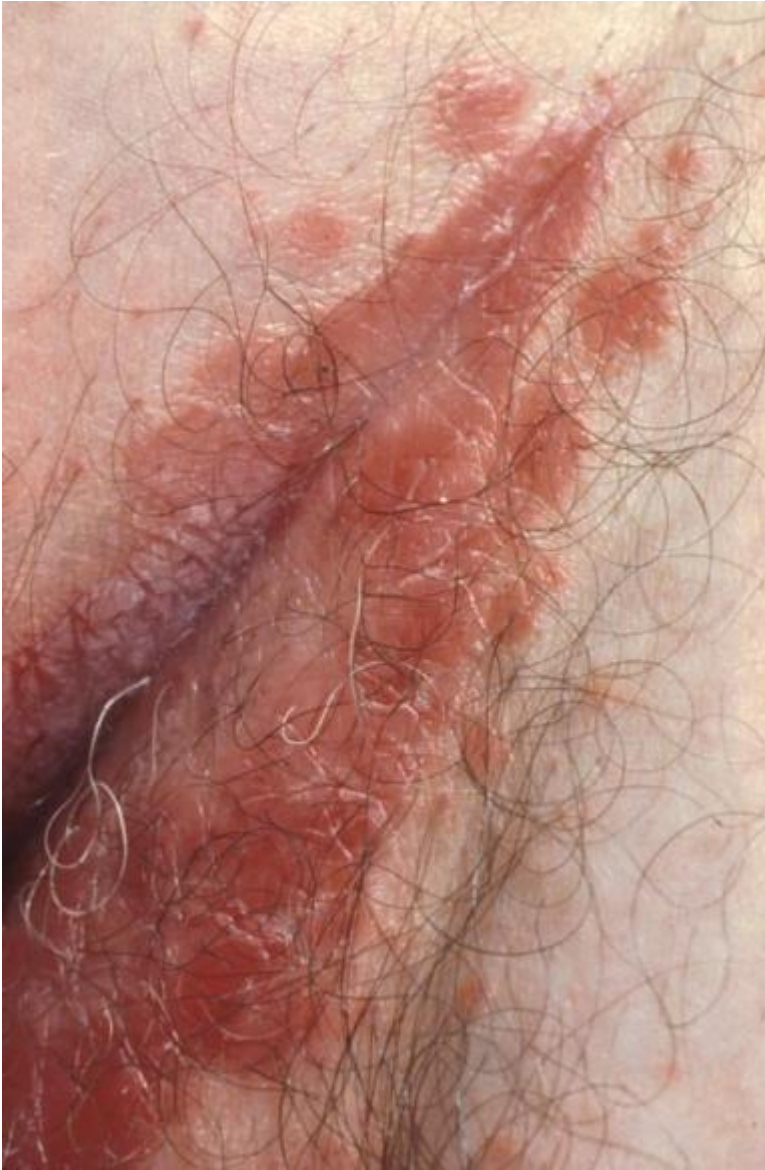Fungal microscopy



Red Scaly Rashes -Fungus

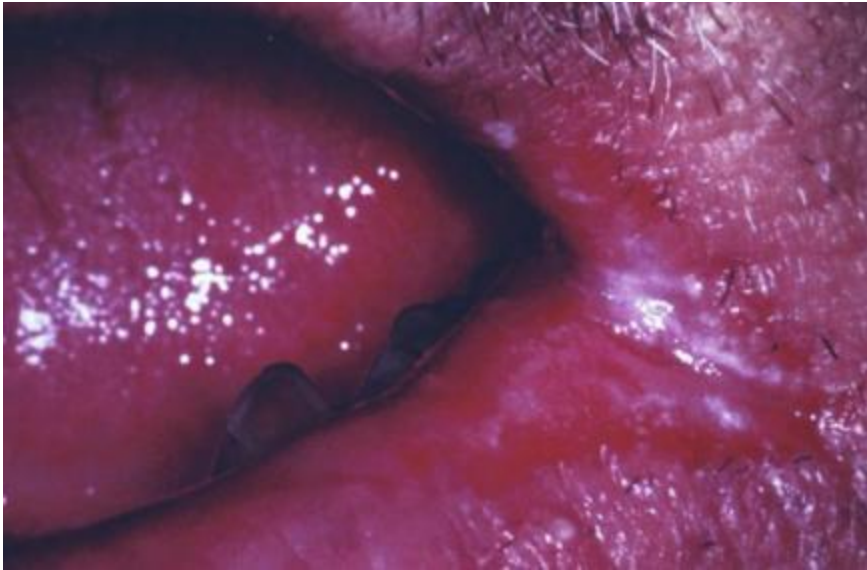- Tinea
- Candida
- Pityriasis Versicolor

Fungus



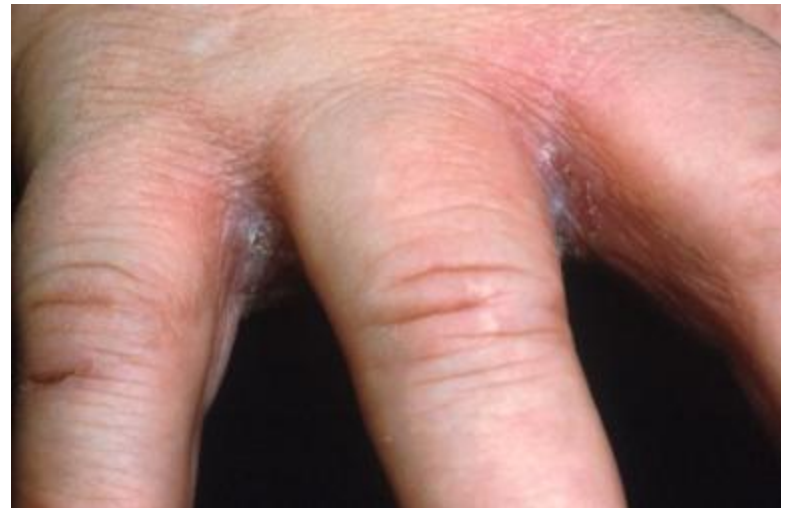Candida intertrigo
(syn. Thrush)

Fungus

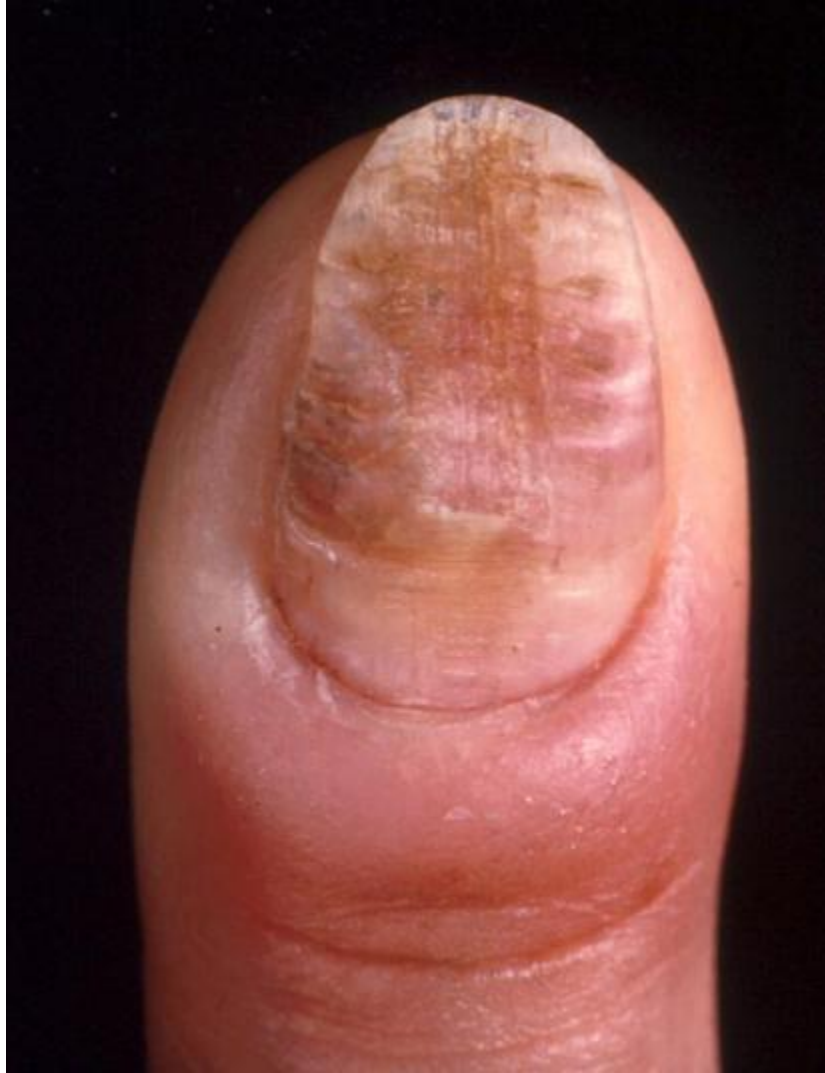

Angular stomatitis

Erosio interdigitale
blastomyces



Fungus

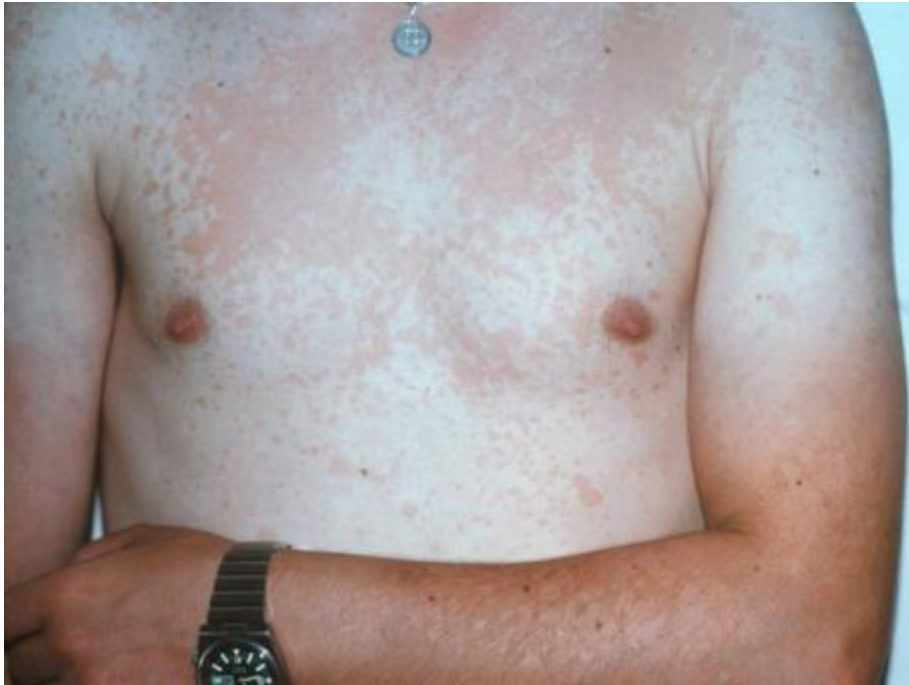

Chronic paronychia

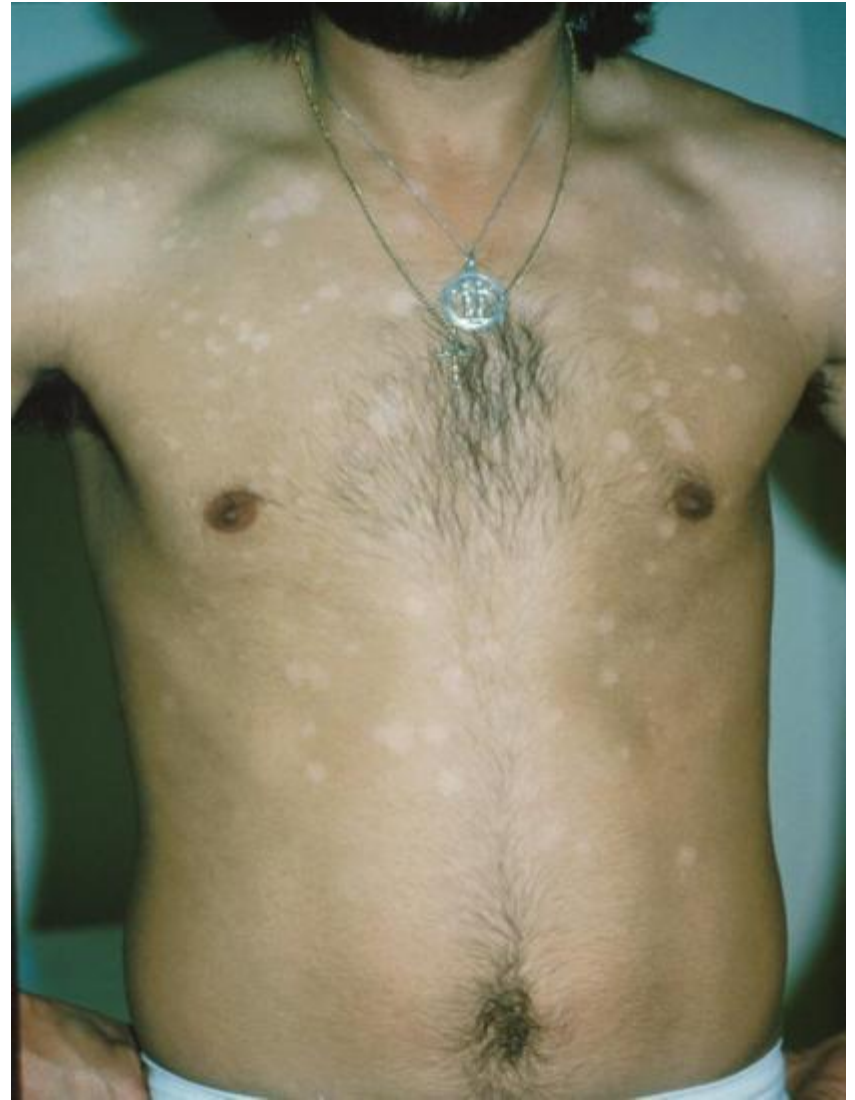
Red Scaly Rashes -Fungus

- Tinea
- Candida
- Pityriasis Versicolor

Fungus

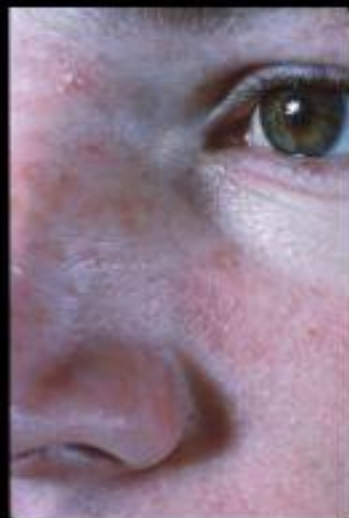

Pityriasis Versicolor
(syn. tinea versicolor)

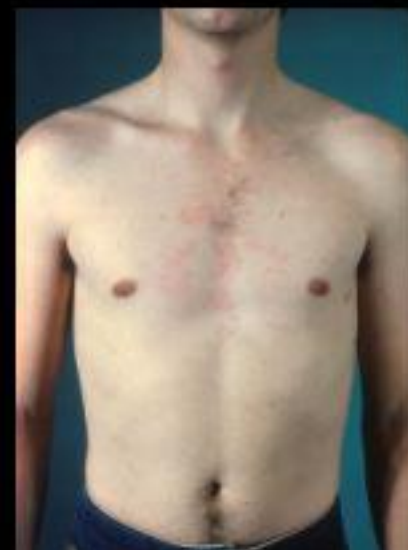
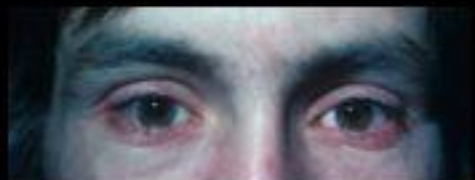
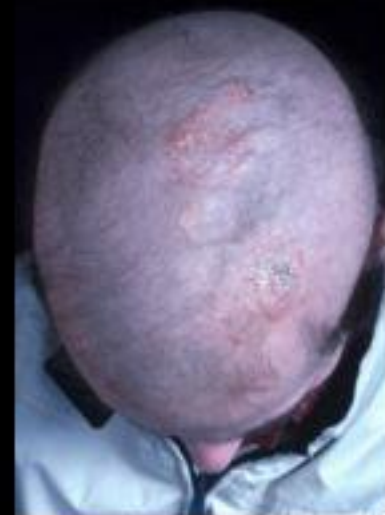Seborrhoeic Dermatitis

Pityriasis



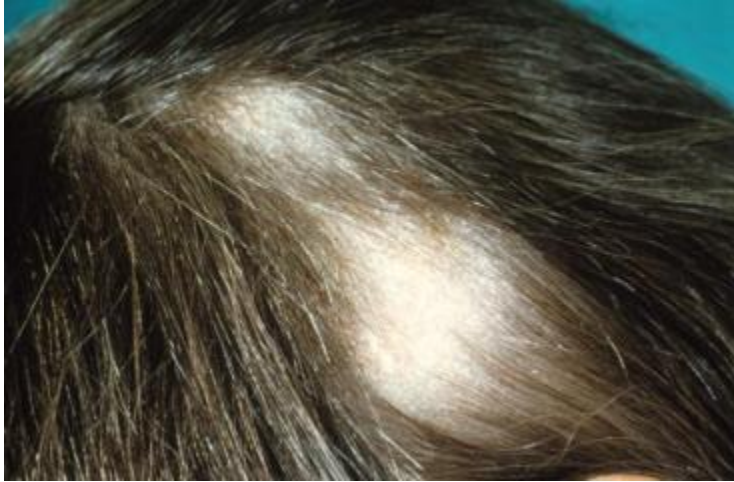Seborrhoeic
Dermatitis



Red Scaly Rashes -Fungus

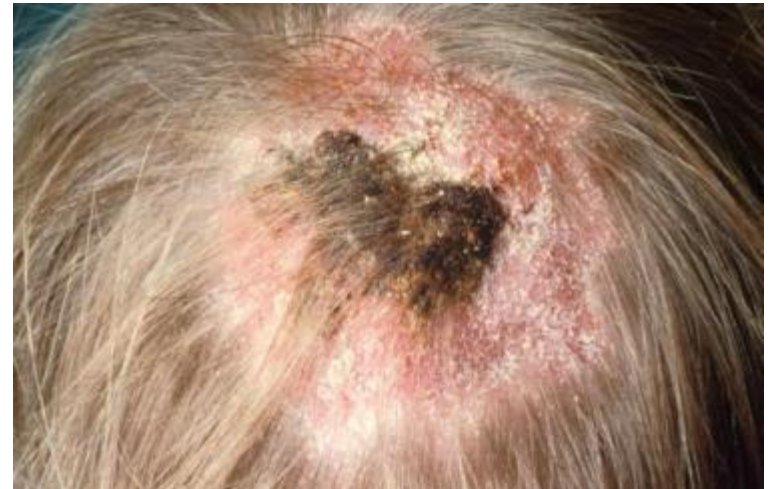- Tinea
- Candida
- Pityriasis Versicolor

Fungus



Tinea capitis
(*M. canis*)

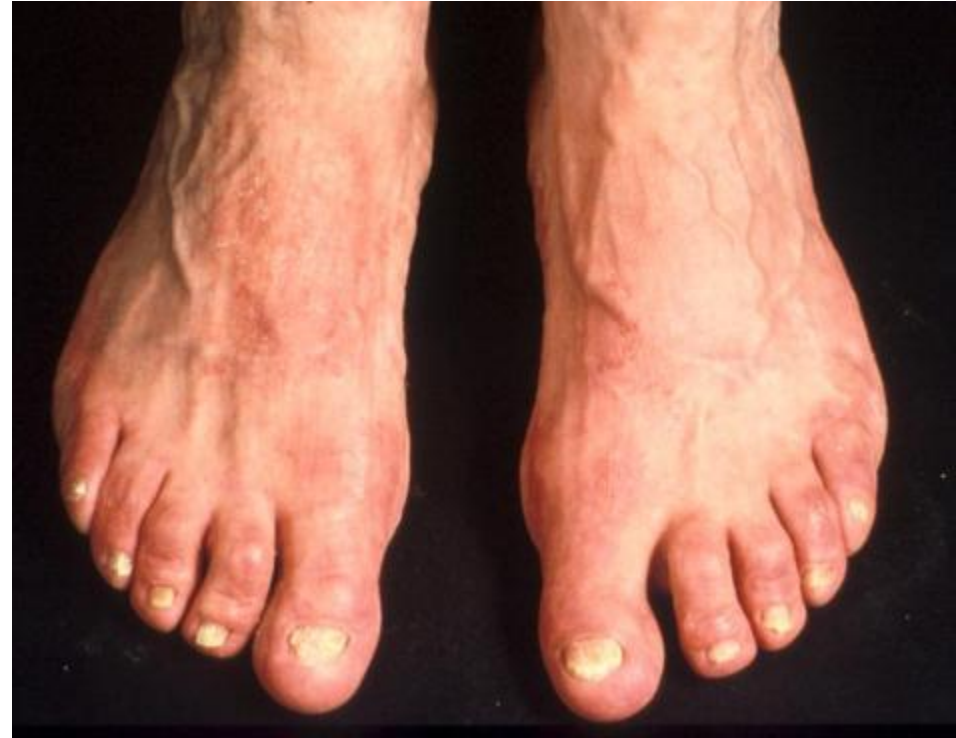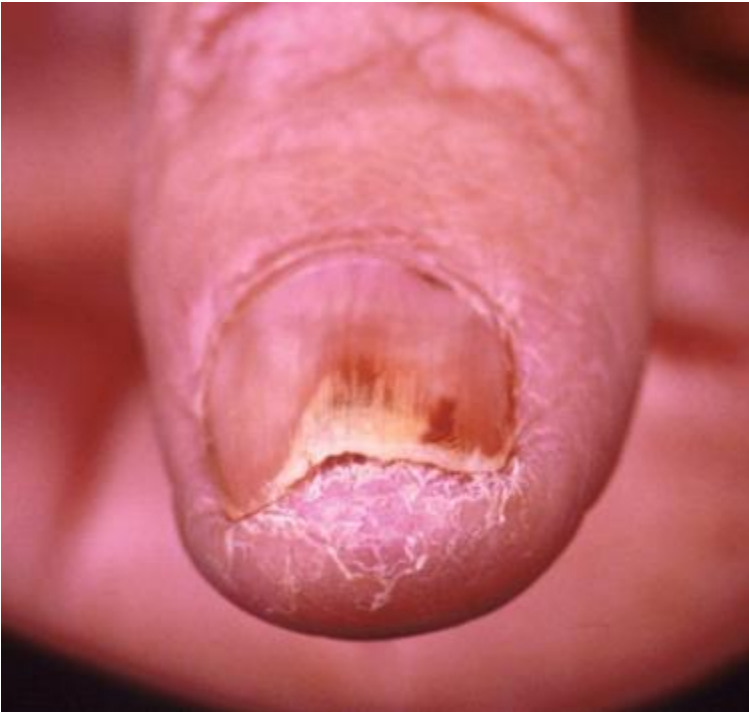Tinea capitis
(Kerion)



Onychomycosis

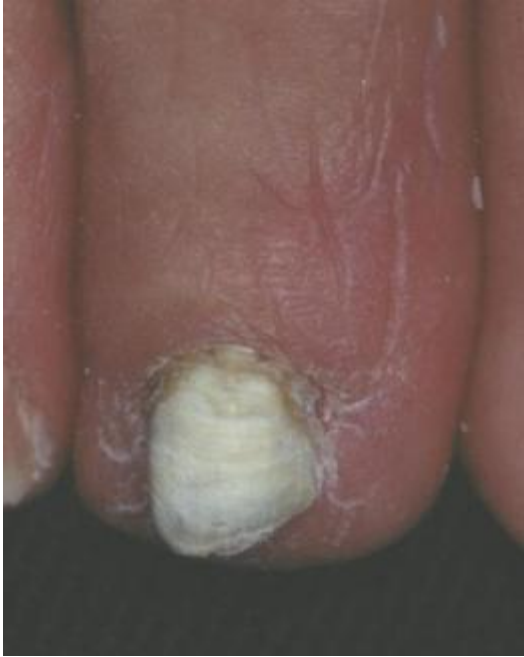- Tinea
- Candida

Fungus

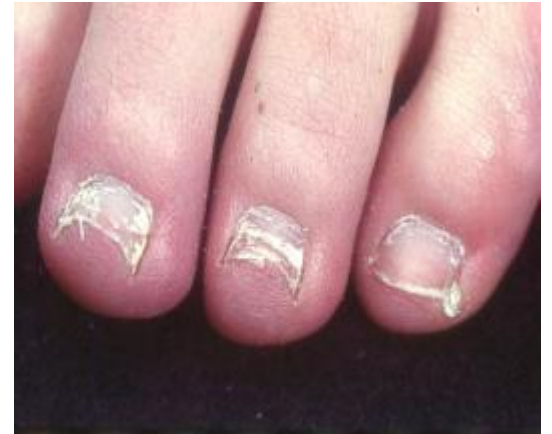
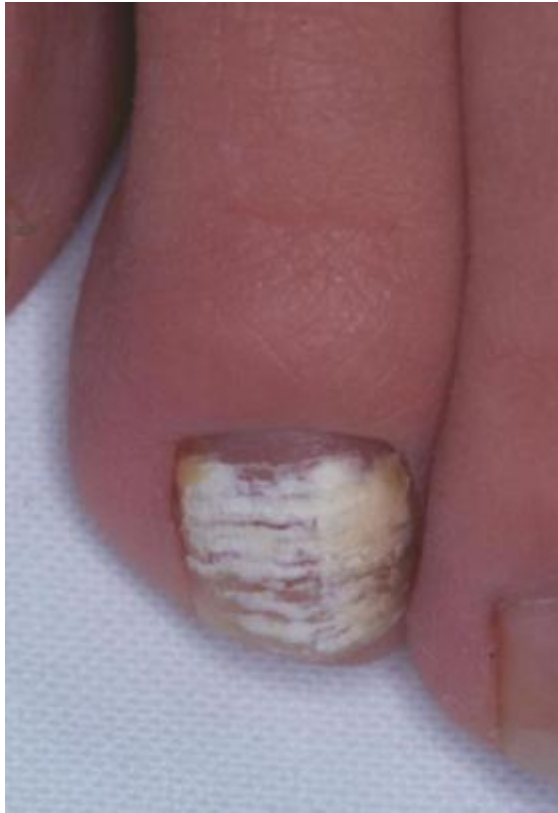
Tinea unguium (onychomycosis)

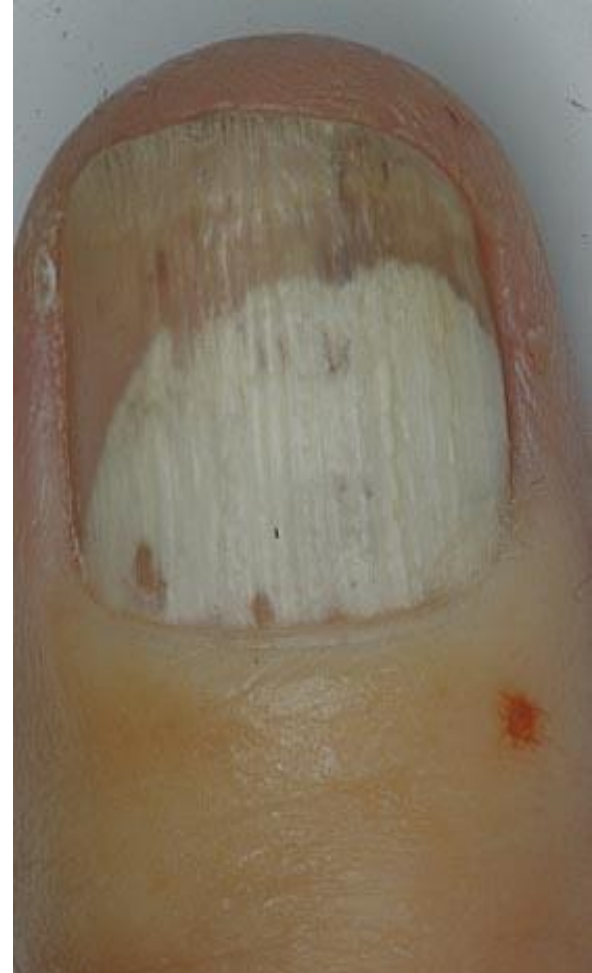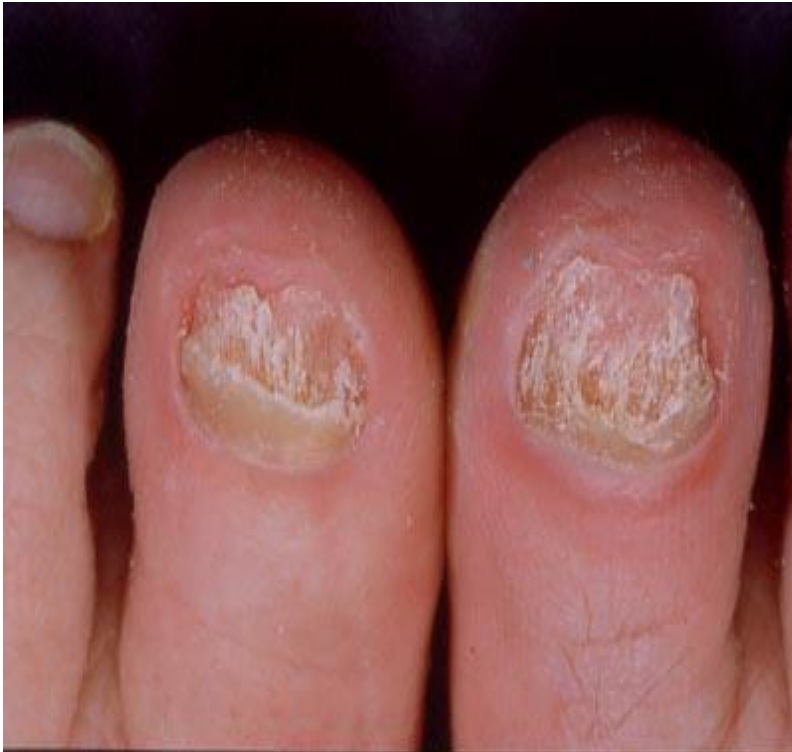Onychomycosis



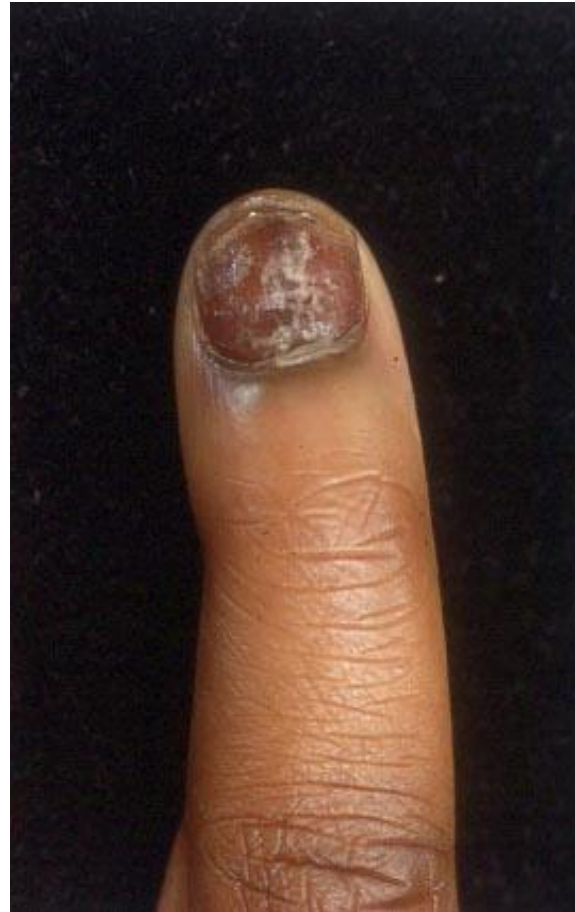WSO



Onychomycosis



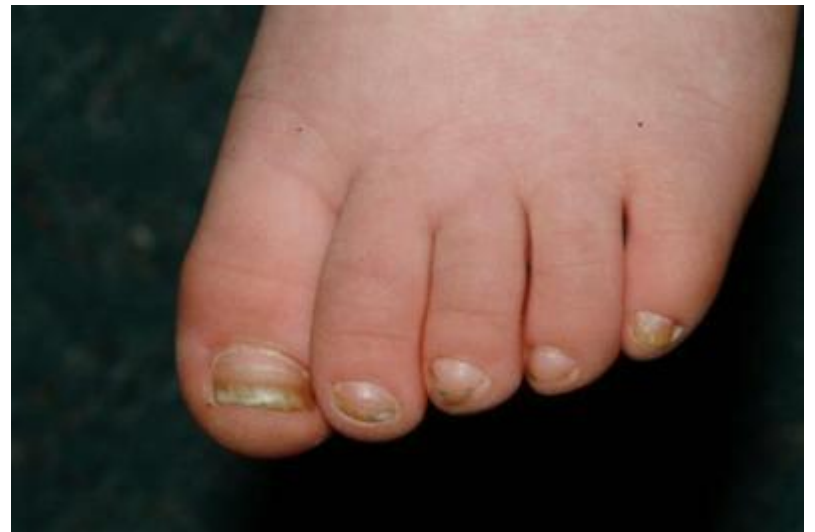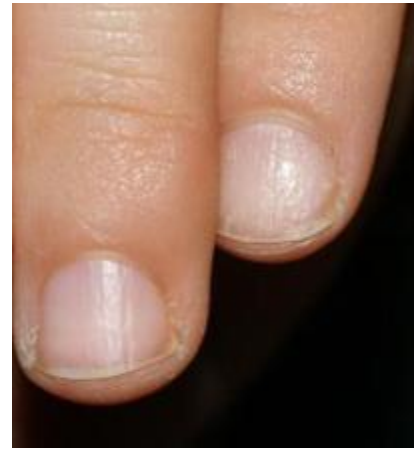
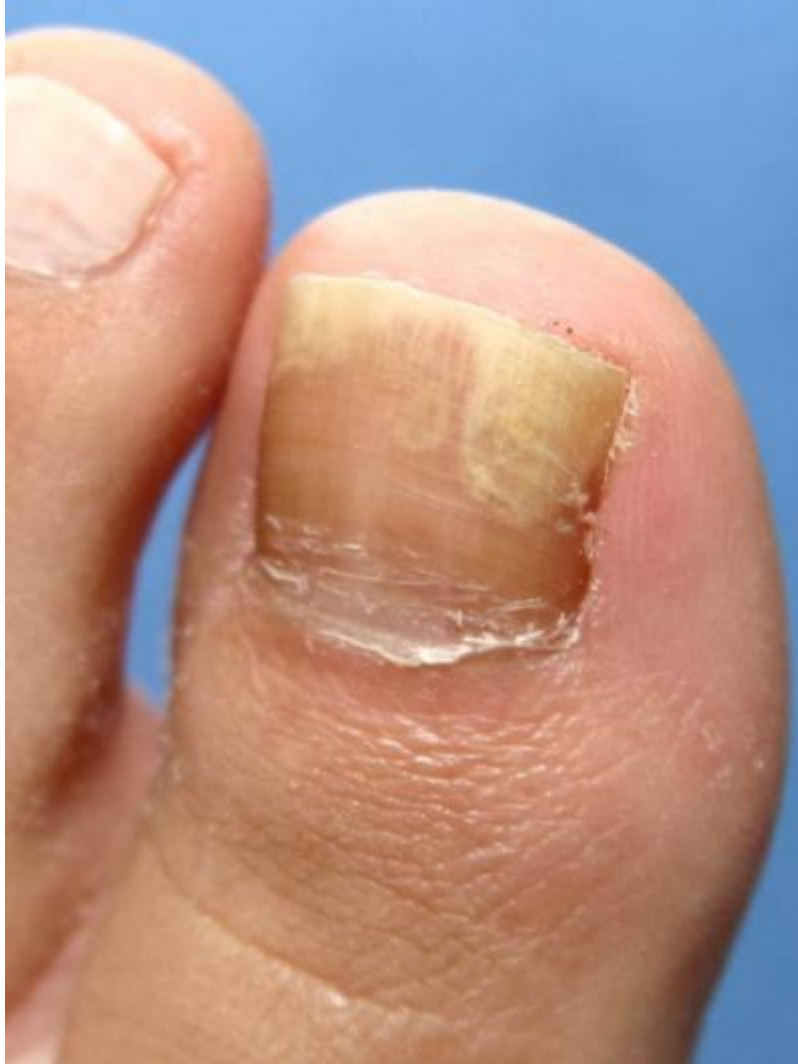Non Dermatophyte Onychomycosis



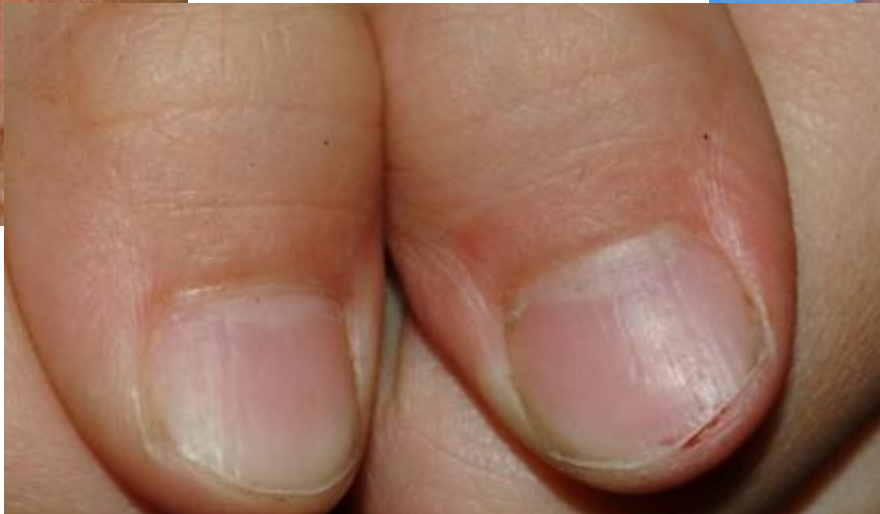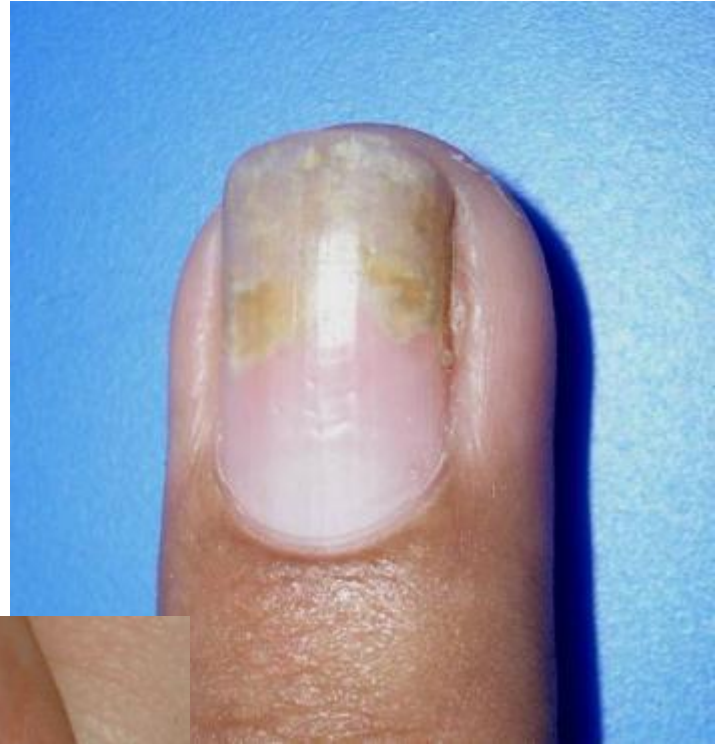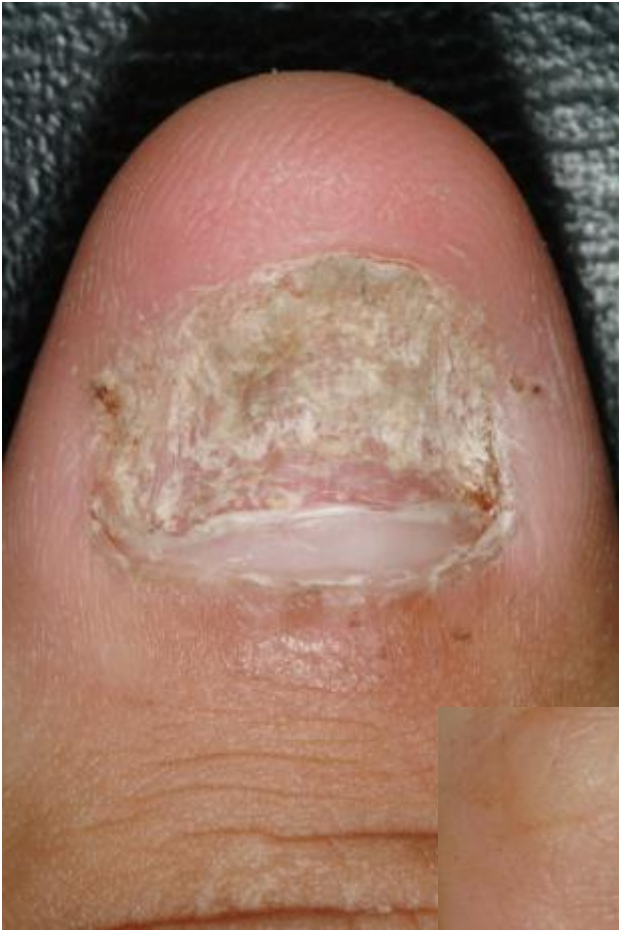Not Every Nail Dystrophy Is Fungal

- Tinea
- Non-dermatophyte fungal infections
- Psoriasis
- Lichen Planus
- Trauma
- Bowen's Disease
- Congenital dystrophy
- Twenty Nail Dystrophy
- Ingrowing Toenail
- Melanoma

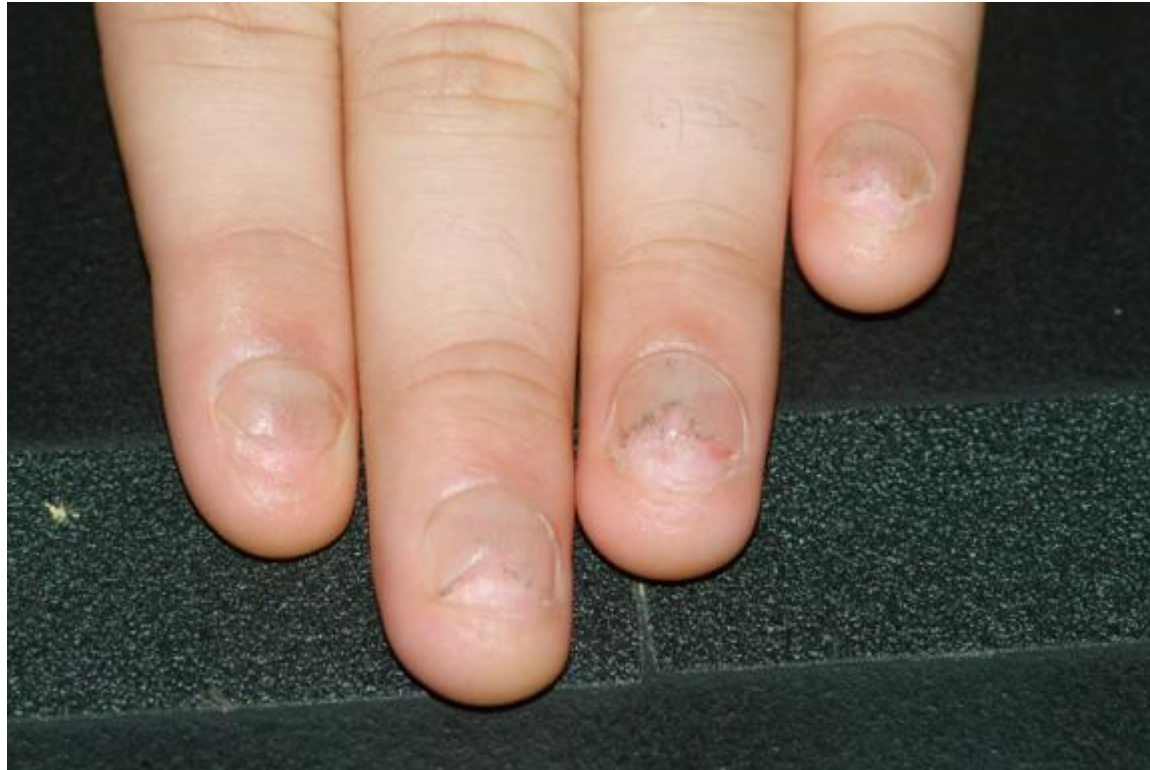Psoriasis



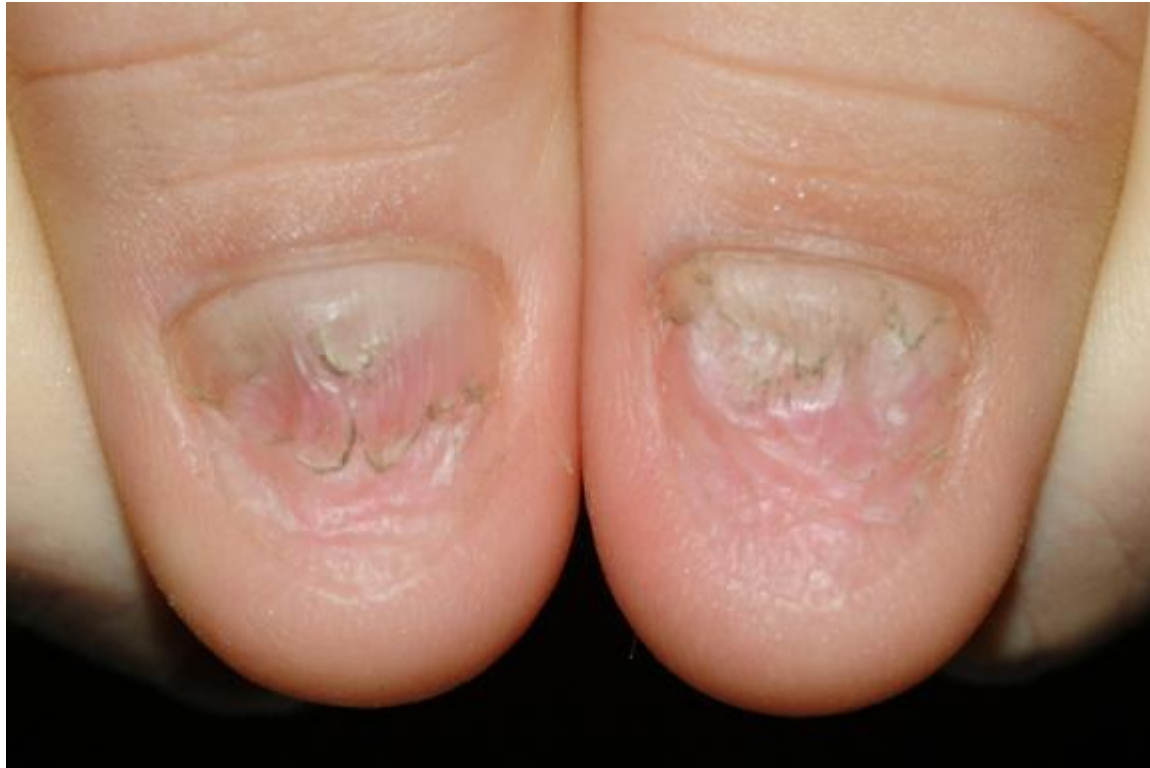Psoriasis



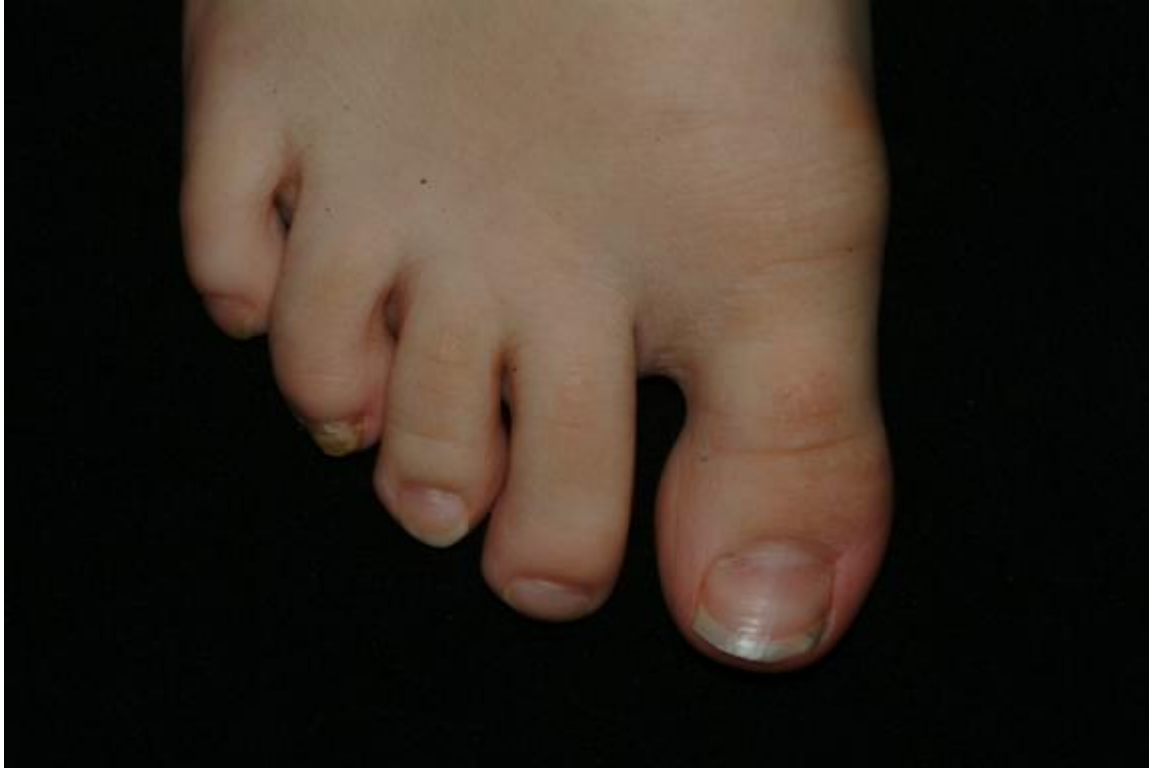Lichen Planus

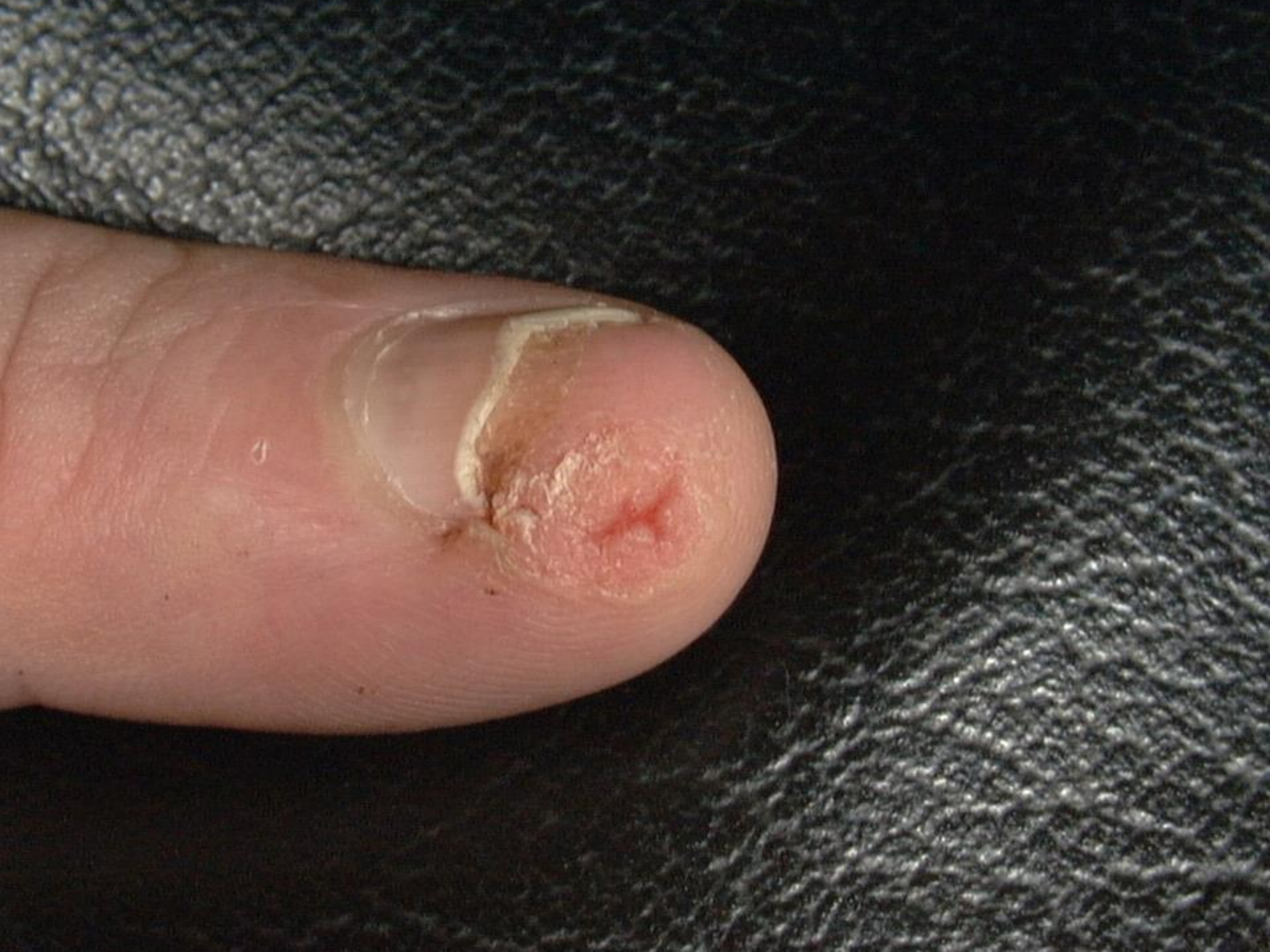

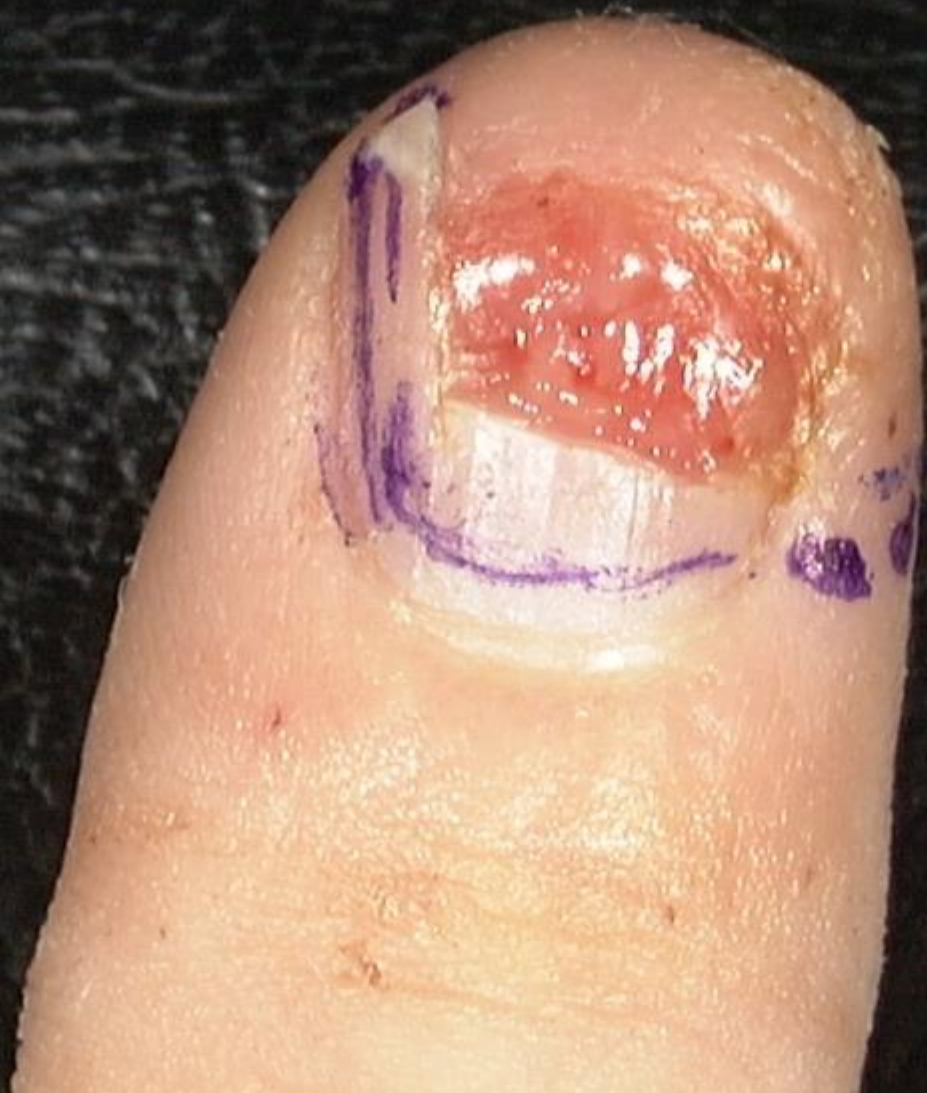Lichen Planus



Traumatic Nail Dystrophy of the 4th toe





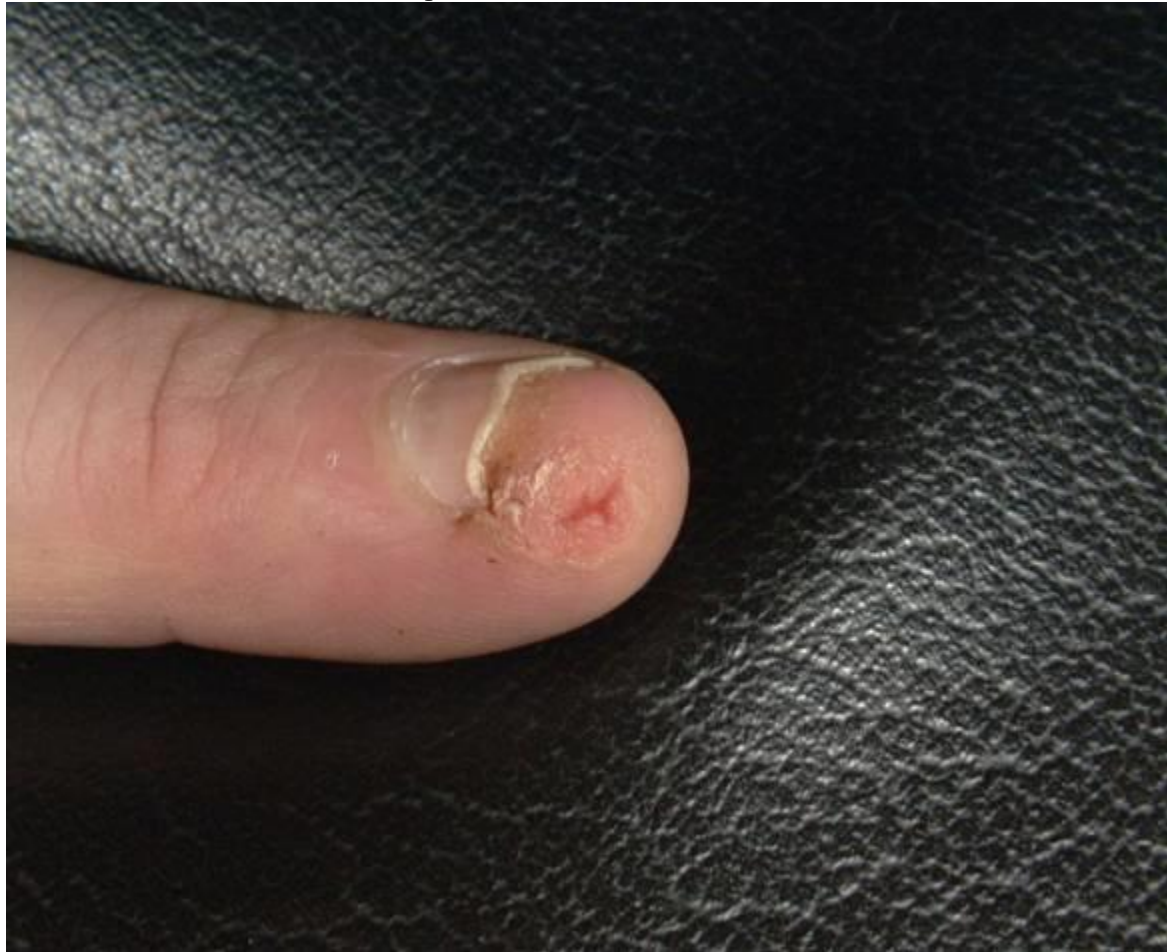

In clinical practice

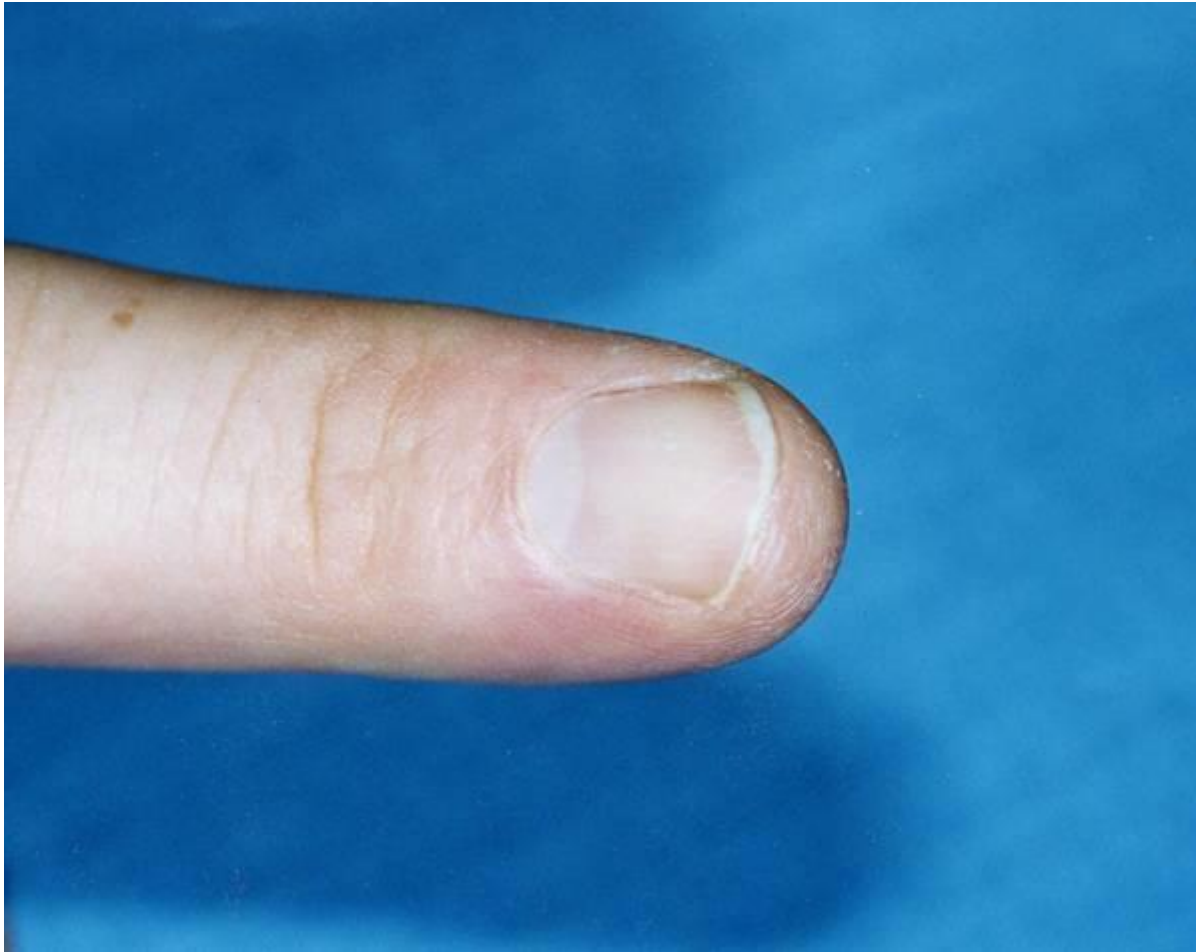Bowen's Case

- **Patient JO**
- **35 year-old male**
- **Police shooting instructor**
- **Periungual Bowen's disease**
- **No response to imiquimod**

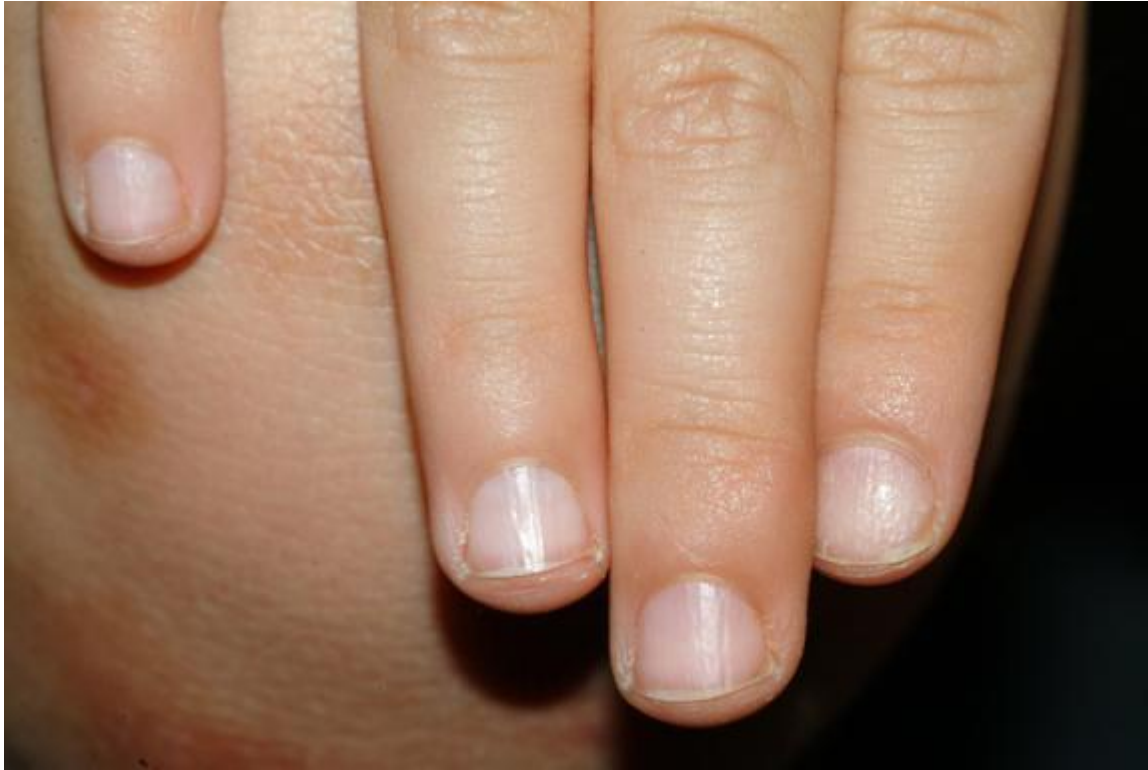Periungual Bowen's disease pre-PDT



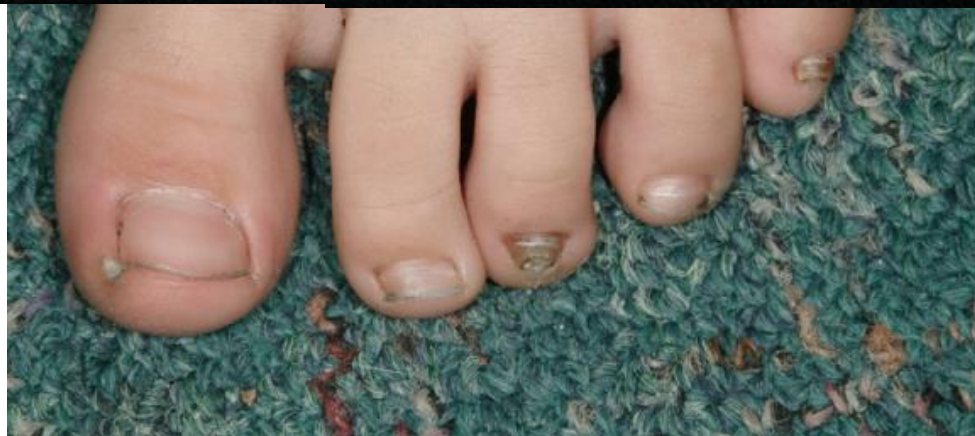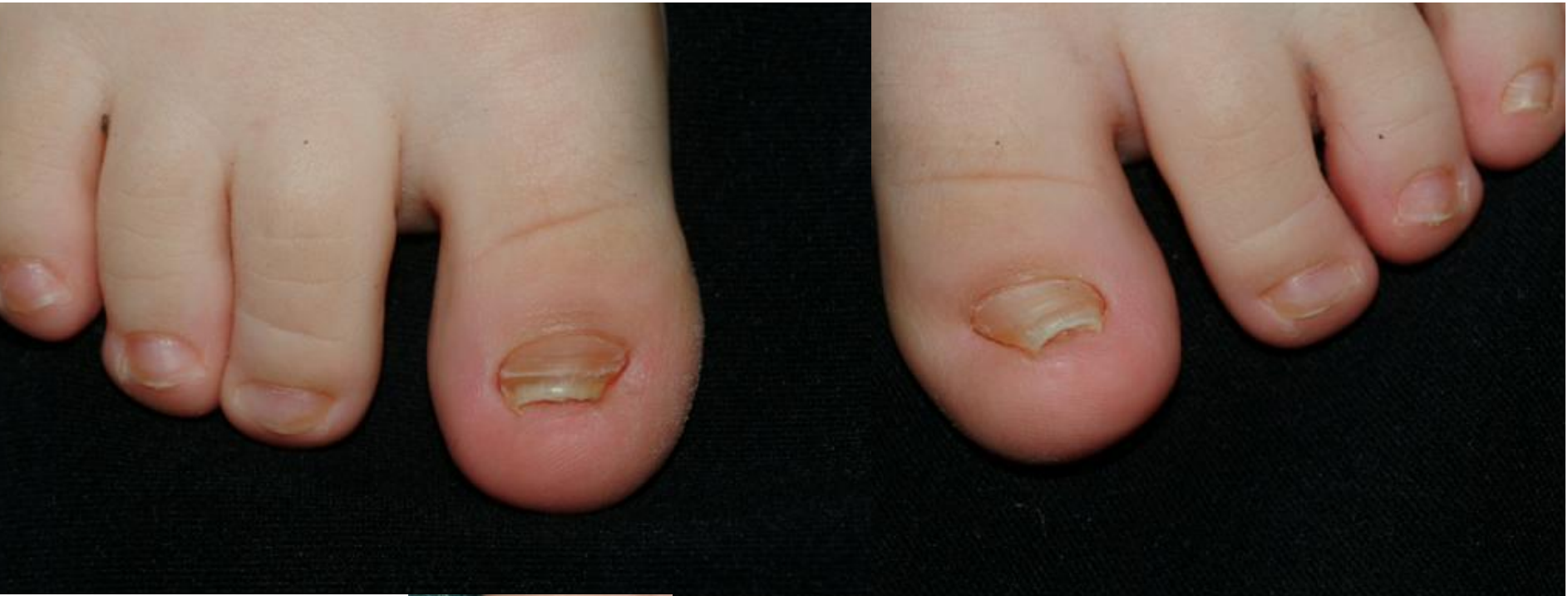Periungual Bowen's disease post-PDT



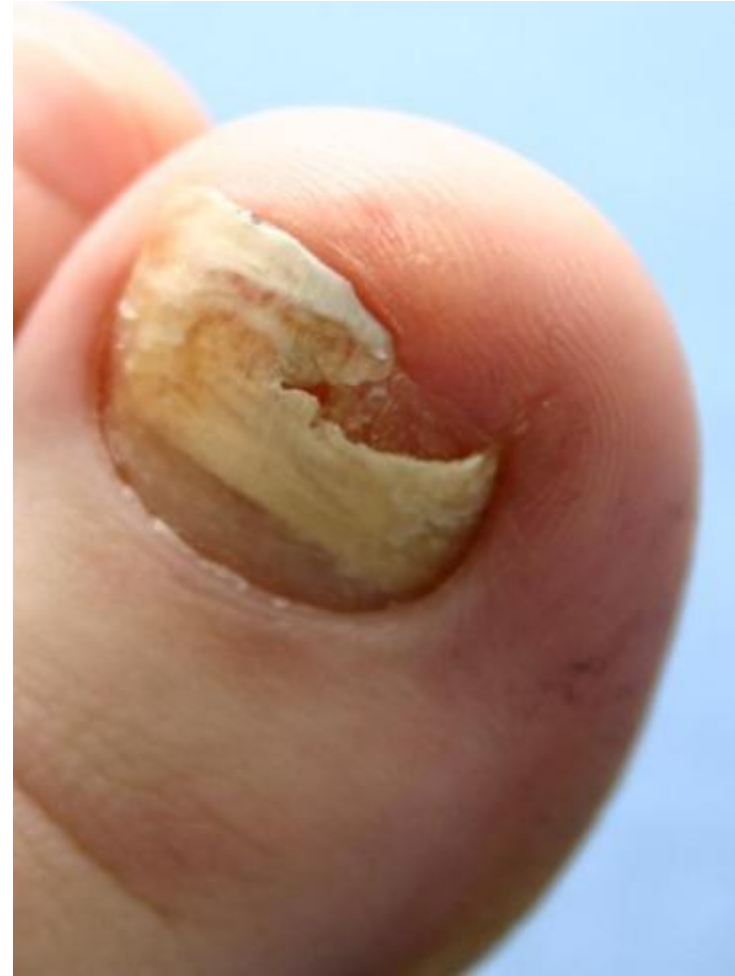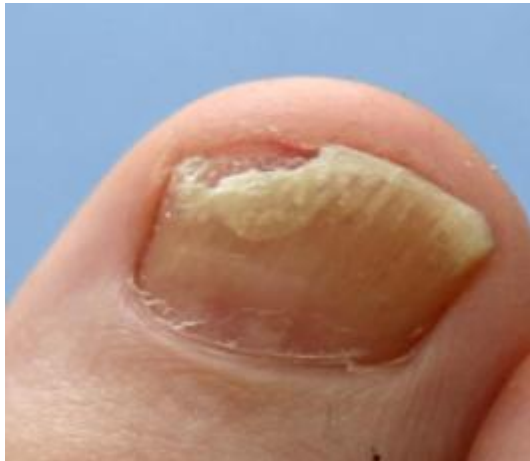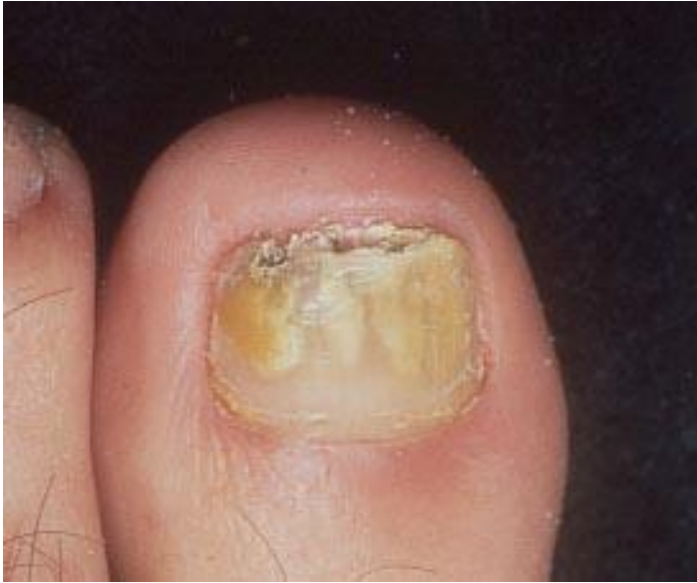Herringbone nails



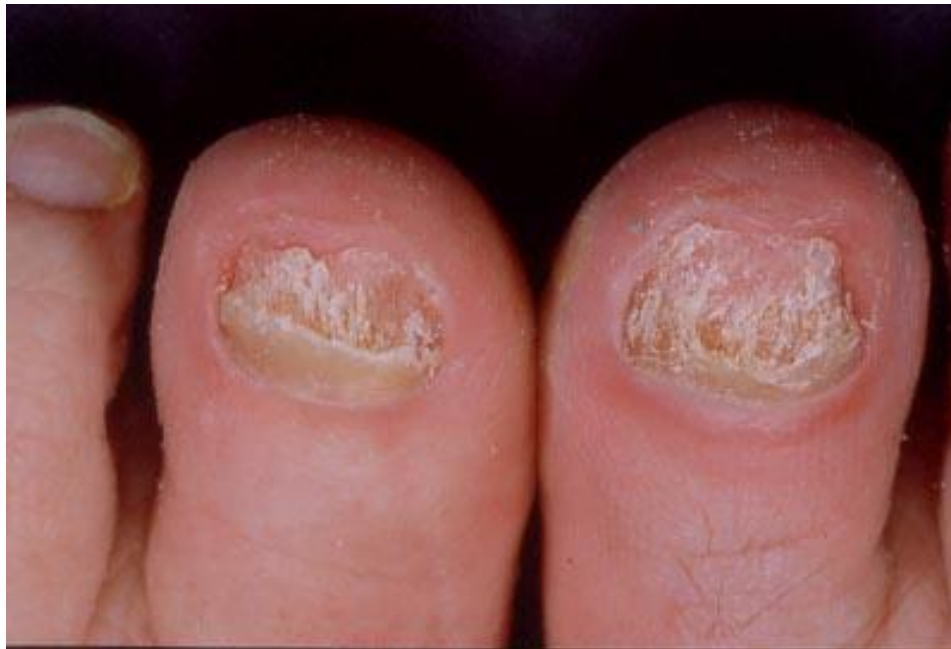Pincer Nail



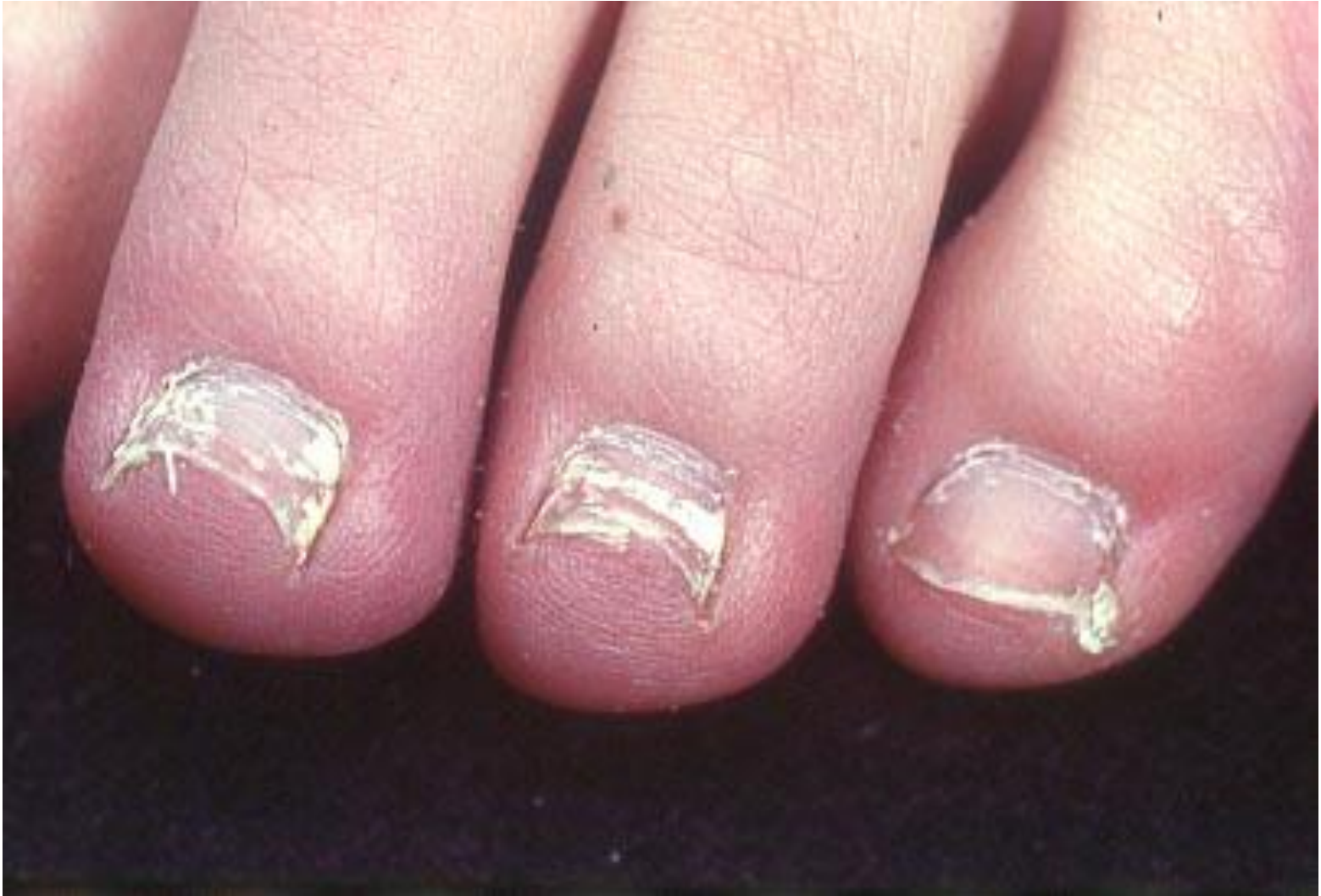Fungal Nail Dystrophy



Fungal Nail Dystrophy



White Superficial Onychomycosis



Treatment of Fungal Nail Disease

Topical

Loceryl

Canesten Nail Fungal Kit

-40% urea 4/52 followed by 1% bifonazole 4/52

Oral

Terbinafine

Fluconazole

Itraconazole

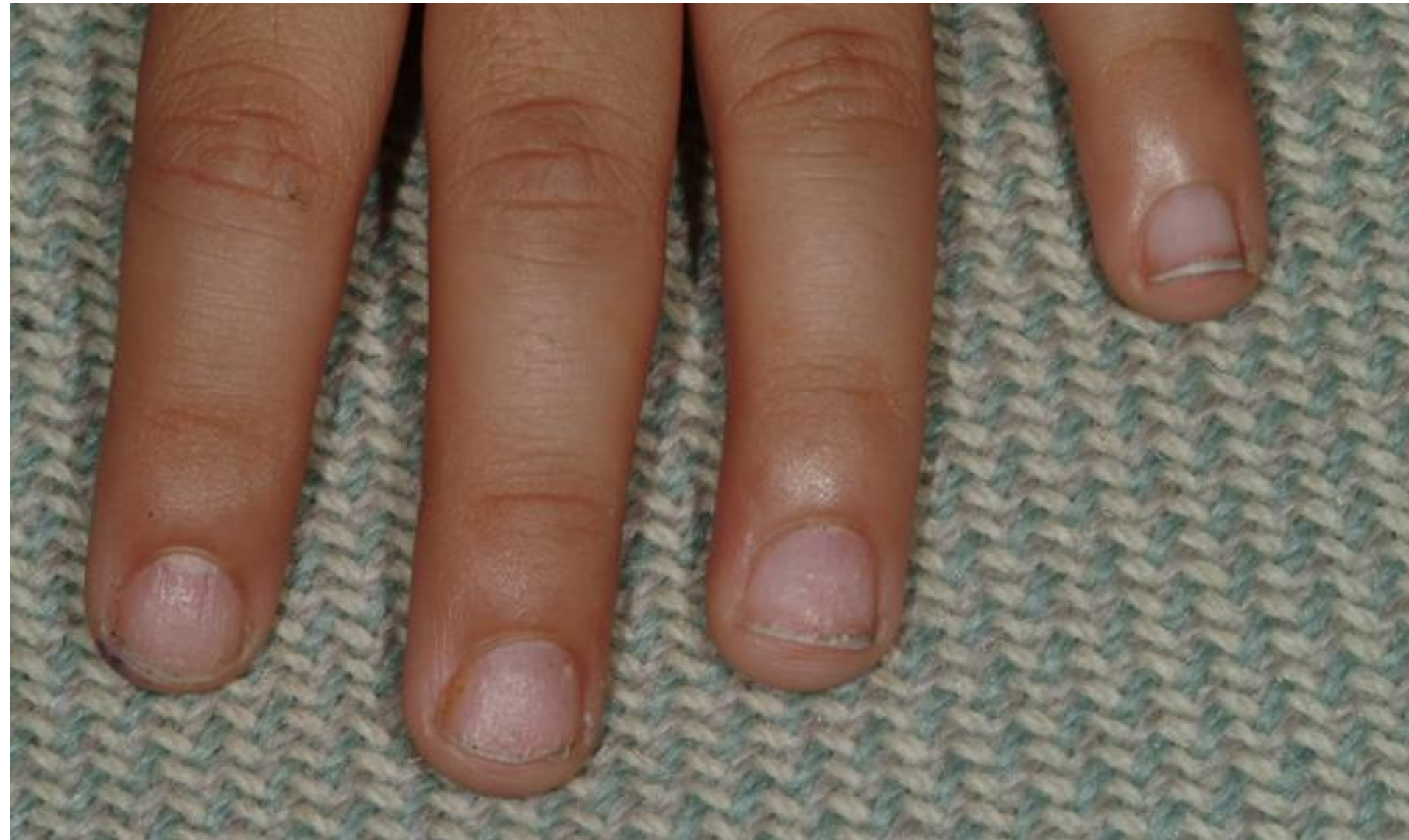Griseogulvin

Physical

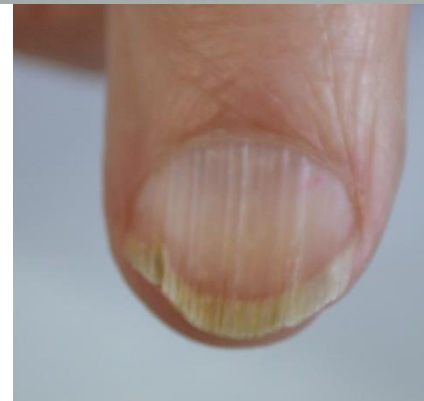
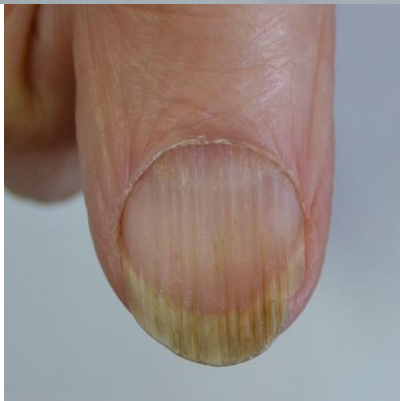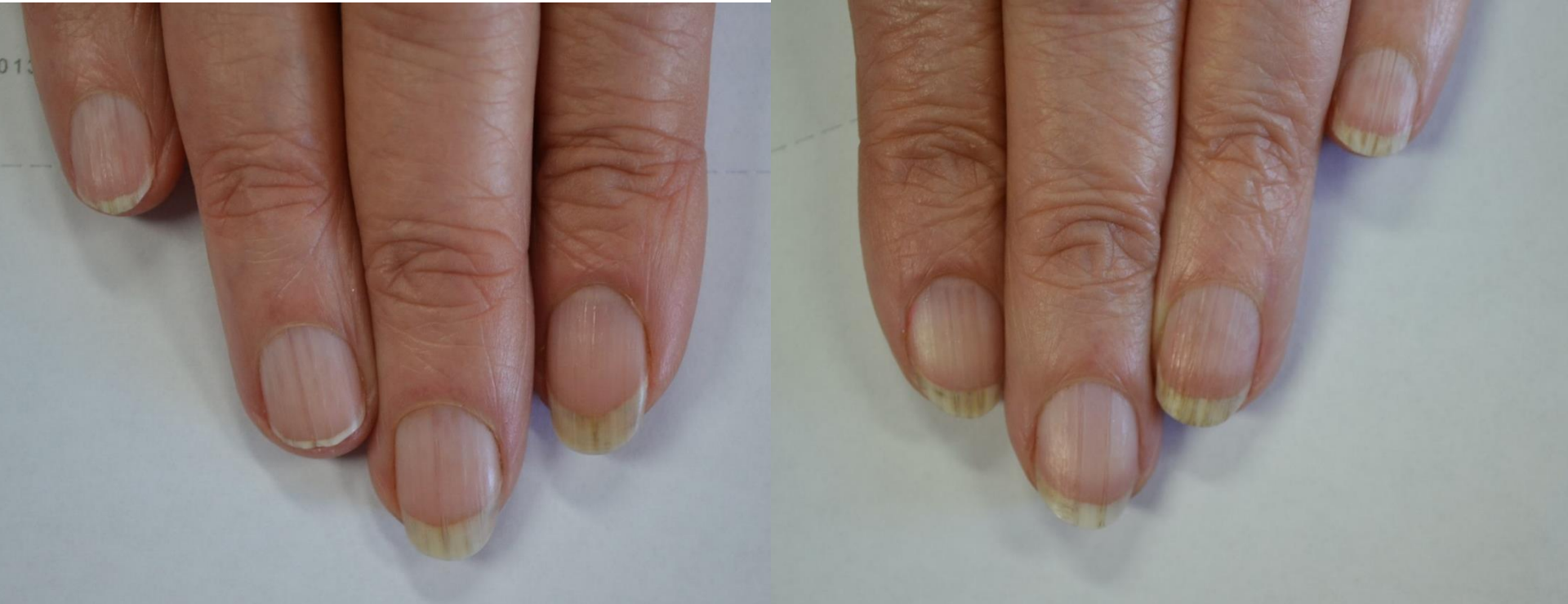Laser

IPL

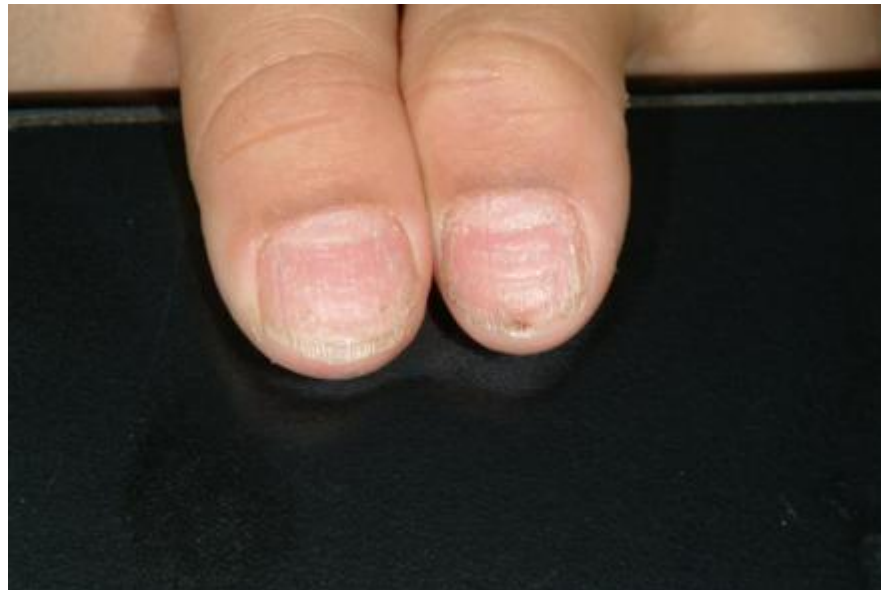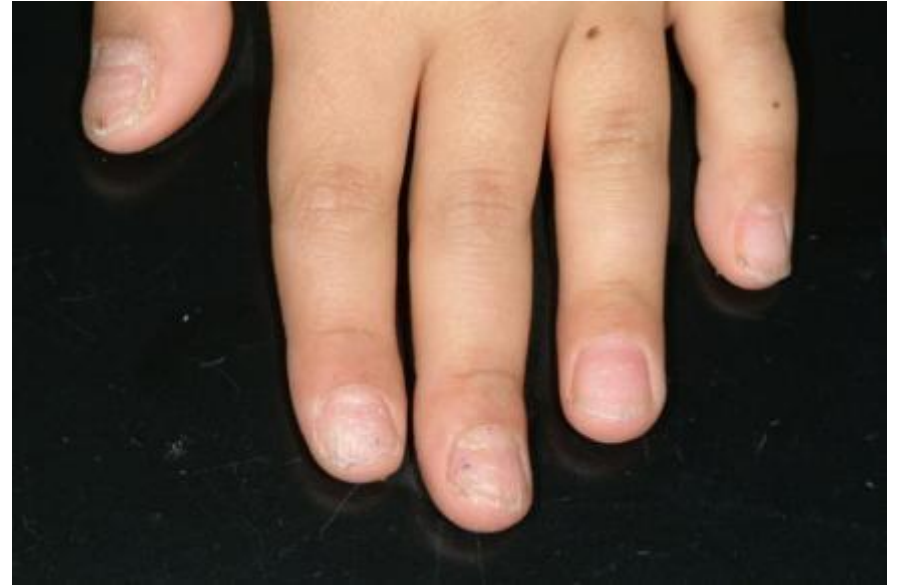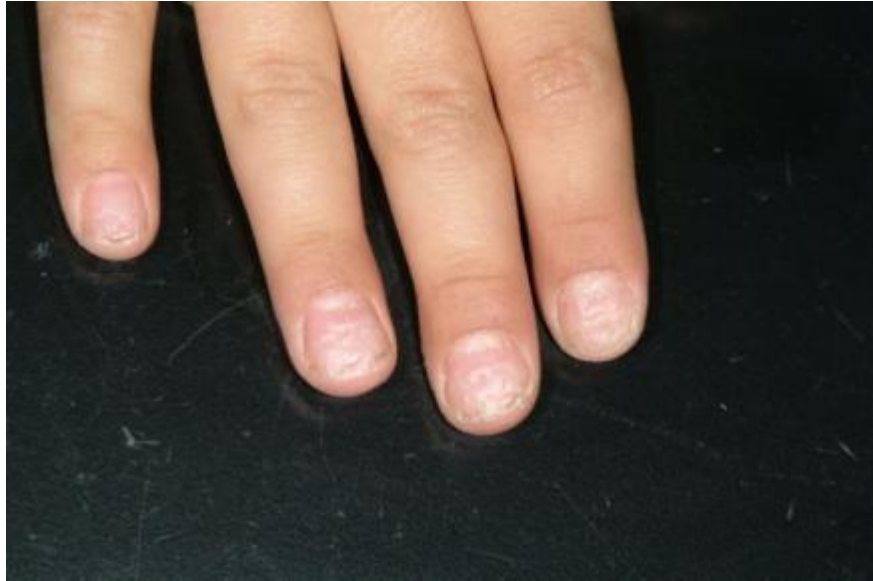Twenty Nail Dystrophy (trachyonychia)

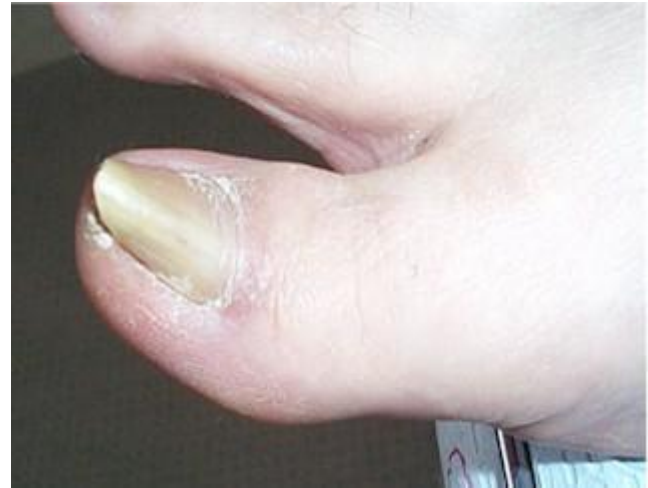
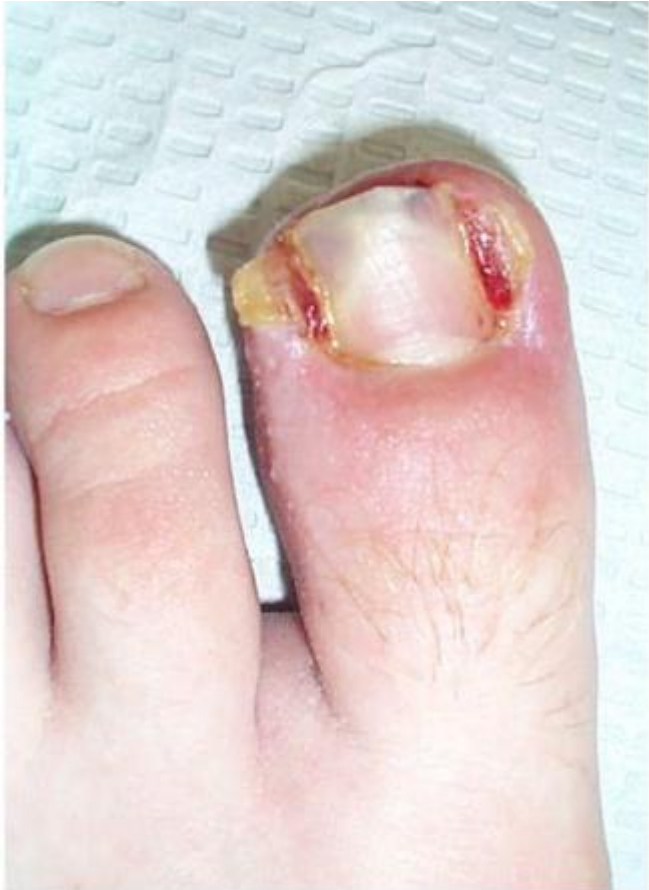
Brittle nails

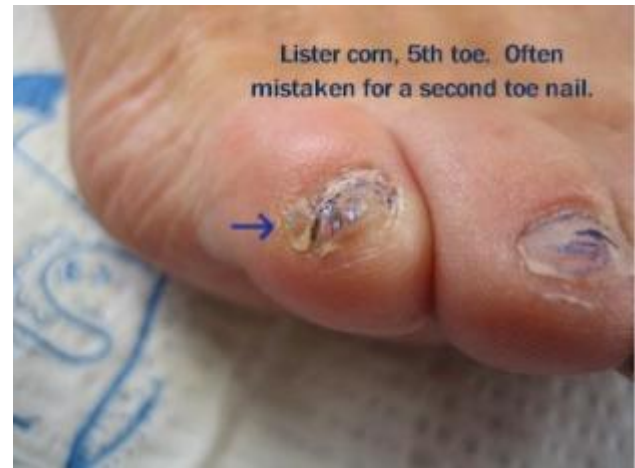
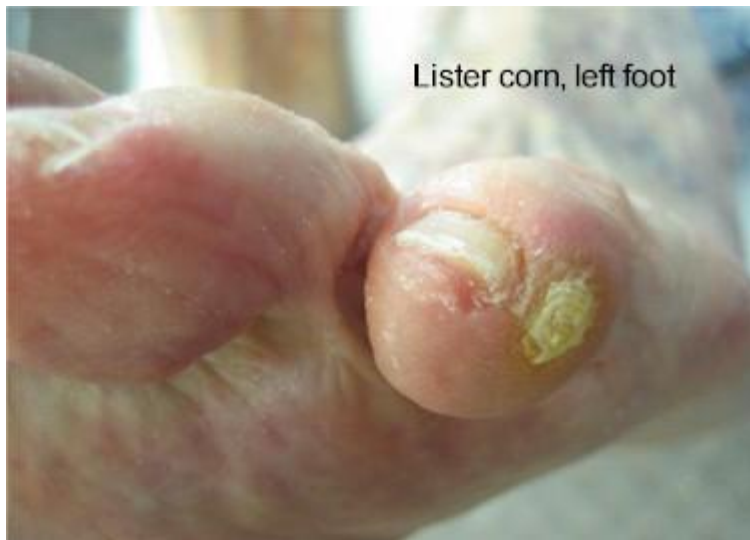
Twenty Nail Dystrophy (trachyonychia)



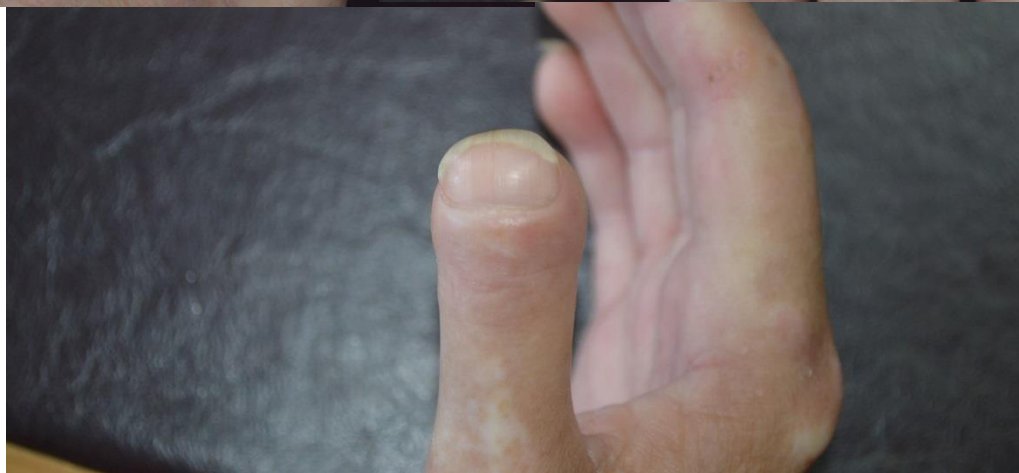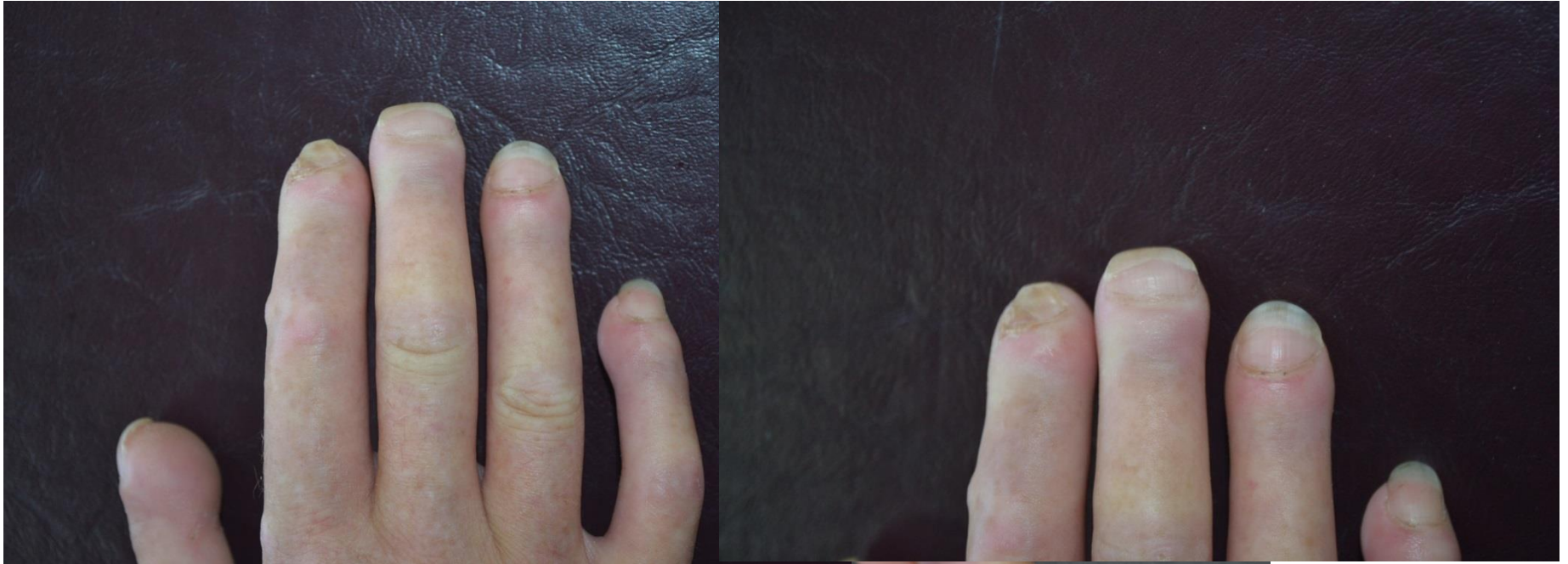


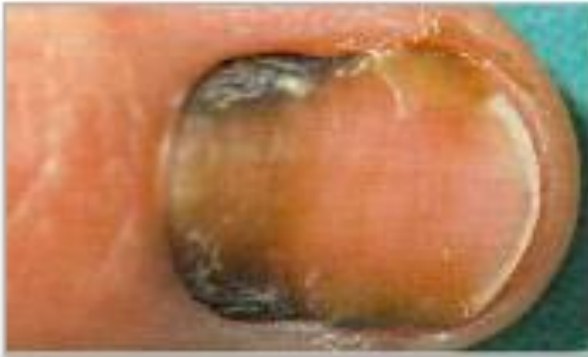Ingrown toenail



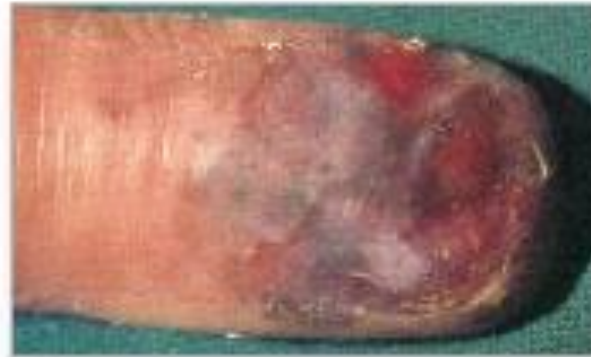Corn and callus

Scleroderma





Onychomycosis



Melanoma